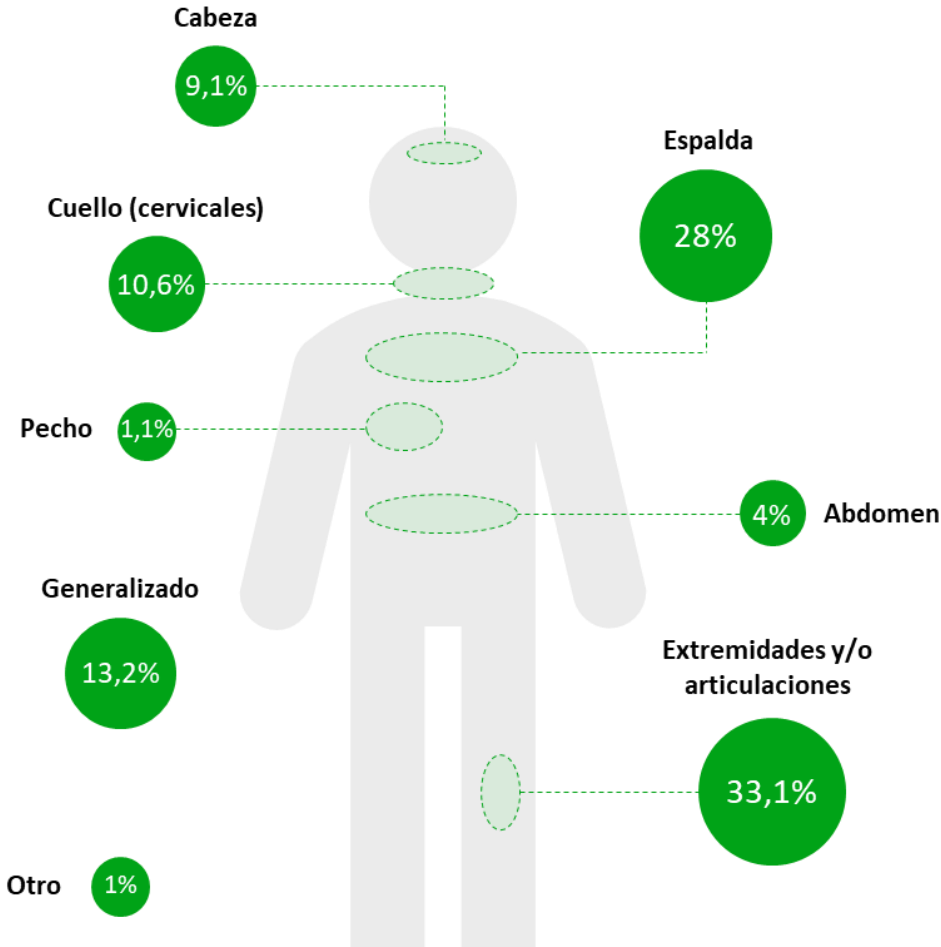

Figura 31. Localizaciones anatómicas del dolor crónico.