
EVIDENCE-BASED MEDICINE

Evidence-Based Interventional Pain Medicine
according to Clinical Diagnoses

11. Lumbosacral Radicular Pain

Koen Van Boxem, MD, FIPP*[†]; Jianguo Cheng, MD, PhD[‡];
Jacob Patijn, MD, PhD*[†]; Maarten van Kleef, MD, PhD, FIPP*[†];
Arno Lataster, MSc[§]; Nagy Mekhail, MD, PhD, FIPP[‡];
Jan Van Zundert, MD, PhD, FIPP*[¶]

**Department of Anesthesiology and Pain Management, Maastricht University Medical Centre, Maastricht, The Netherlands; [†]Department of Anesthesiology and Pain Management, Sint-Jozefkliniek, Bornem and Willebroek, Bornem, Belgium; [‡]Department of Pain Management, Cleveland Clinic, Cleveland, Ohio, U.S.A.; [§]Department of Anatomy and Embryology, Maastricht University, Maastricht, the Netherlands; [¶]Department of Anesthesiology and Multidisciplinary Pain Centre, Ziekenhuis Oost-Limburg, Genk, Belgium*

■ **Abstract:** Lumbosacral radicular pain is characterized by a radiating pain in one or more lumbar or sacral dermatomes; it may or may not be accompanied by other radicular irritation symptoms and/or symptoms of decreased function. The annual prevalence in the general population, described as low back pain with leg pain traveling below the knee, varied from 9.9% to 25%, which means that it is presumably the most commonly occurring form of neuropathic pain.

The patient's history may give a suggestion of lumbosacral radicular pain. The best known clinical investigation is the straight-leg raising test. Final diagnosis is made based on a combination of clinical examination and potentially additional tests. Medical imaging studies are indicated to exclude possible serious pathologies and to confirm the affected level in patients suffering lumbosacral radicular pain for longer than 3 months. Magnetic resonance imaging is preferred. Selective diagnostic blocks help confirming the affected level.

There is controversy concerning the effectiveness of conservative management (physical therapy, exercise) and pharmacological treatment.

When conservative treatment fails, in subacute lumbosacral radicular pain under the level L3 as the result of a contained herniation, transforaminal corticosteroid administration is recommended (2 B+). In chronic lumbosacral radicular pain, (pulsed) radiofrequency treatment adjacent to the spinal ganglion (DRG) can be considered (2 C+). For refractory lumbosacral radicular pain, adhesiolysis and epiduroscopy can be considered (2 B±), preferentially study-related.

In patients with a therapy-resistant radicular pain in the context of a Failed Back Surgery Syndrome, spinal cord stimulation is recommended (2 A+). This treatment should be performed in specialized centers. ■

Key Words: lumbosacral radicular pain, epidural corticosteroids, pulsed radiofrequency treatment, evidence-based medicine

INTRODUCTION

This review on lumbosacral radicular pain is part of the series “Evidence-based Interventional Pain Medicine According to Clinical Diagnoses.” Recommendations formulated in this article are based on “Grading strength of recommendations and quality of evidence in

Address correspondence and reprint requests to: Koen Van Boxem, MD, FIPP, Department of Anesthesiology and Pain Therapy, St.-Jozefkliniek, Bornem and Willebroek, Kasteelstraat 23, 2880 Bornem, Belgium. E-mail: koen.vb@telenet.be.

DOI: 10.1111/j.1533-2500.2010.00370.x

Table 1. Summary of Evidence Scores and Implications for Recommendation

Score	Description	Implication
1 A+	Effectiveness demonstrated in various RCTs of good quality. The benefits clearly outweigh risk and burdens	Positive recommendation
1 B+	One RCT or more RCTs with methodologic weaknesses, demonstrate effectiveness. The benefits clearly outweigh risk and burdens	
2 B+	One or more RCTs with methodologic weaknesses, demonstrate effectiveness. Benefits closely balanced with risk and burdens	
2 B±	Multiple RCTs, with methodologic weaknesses, yield contradictory results better or worse than the control treatment. Benefits closely balanced with risk and burdens, or uncertainty in the estimates of benefits, risk and burdens.	Considered, preferably study-related
2 C+	Effectiveness only demonstrated in observational studies. Given that there is no conclusive evidence of the effect, benefits closely balanced with risk and burdens	
0	There is no literature or there are case reports available, but these are insufficient to suggest effectiveness and/or safety. These treatments should only be applied in relation to studies.	Only study-related
2 C-	Observational studies indicate no or too short-lived effectiveness. Given that there is no positive clinical effect, risk and burdens outweigh the benefit	Negative recommendation
2 B-	One or more RCTs with methodologic weaknesses, or large observational studies that do not indicate any superiority to the control treatment. Given that there is no positive clinical effect, risk and burdens outweigh the benefit	
2 A-	RCT of a good quality which does not exhibit any clinical effect. Given that there is no positive clinical effect, risk and burdens outweigh the benefit	

RCT, randomized controlled trial.

clinical guidelines” described by Guyatt et al.,¹ and adapted by van Kleef et al.² in the editorial accompanying the first article of this series (Table 1).

The latest literature update was performed in December 2009.

A lumbosacral radicular syndrome (LSR) is characterized by a radiating pain in one or more lumbar or sacral dermatomes; it may or may not be accompanied by other radicular irritation symptoms and/or symptoms of decreased function. In the literature, this disorder can also be referred to as sciatica, ischias, or nerve root pain. A consensus approach toward standardization of back pain definitions clearly highlights huge differences in the description of low back pain, which makes comparison of epidemiological data extremely difficult.³ The terms radicular pain and radiculopathy are also sometimes used interchangeably, although they certainly are not synonyms. In the case of radicular pain, only radiating pain is present, while in the case of radiculopathy, sensory and/or motor loss that can be objectified can be observed. Both syndromes frequently occur together and radiculopathy can be a continuum of radicular pain. In this review, lumbosacral radicular pain is considered as pain radiating into one or more dermatomes caused by nerve root irritation/inflammation and/or compression.

The annual prevalence in the general population, described as low back pain with leg pain traveling below the knee, varied from 9.9% to 25%. Also the point

prevalence (4.6% to 13.4%) and lifetime prevalence (1.2% to 43%) are very high,⁴ which means that lumbosacral radicular pain is presumably the most commonly occurring form of neuropathic pain.^{5,6} The most important risk factors are: being male, obesity, smoking, history of lumbalgia, anxiety and depression, work which requires lengthy periods of standing and bending forward, heavy manual labor, lifting heavy objects, and being exposed to vibration.⁷

Pain completely or partially resolves in 60% of the patients within 12 weeks of onset.⁸ However, about 30% of the patients still have pain after 3 months to 1 year. Apparently, the female population with LRS has a considerably worse outcome compared with the male population. The estimated unadjusted odd for a long-term poor outcome was 3.3 times higher for female patients than for males.⁹

In patients under 50 years of age, a herniated disc is the most frequent cause of an LSR. After the age of 50, radicular pain is often caused by degenerative changes in the spine (eg, stenosis of the foramen intervertebrale).¹⁰

I. DIAGNOSIS

I.A HISTORY

The patient may experience the radiating pain as sharp, dull, piercing, throbbing, or burning. Pain caused by a herniated disc classically increases by bending forward, sitting, coughing, or (excessive) stress on the lumbar

discs and can be avoided by lying down or sometimes by walking.⁷ Inversely, pain from a lumbar spinal canal stenosis can typically increase when walking and improve immediately upon bending forward.¹⁰ In addition to the pain, the patients also often report paresthesia in the affected dermatome. The distribution of pain along a dermatome can be indicative in the determination of the level involved; however, there is a large variation in radiation pattern. **The S1 dermatome seems the most reliable.**¹¹ If present, the dermatomal distribution of paresthesia is more specific.¹⁰

I.B PHYSICAL EXAMINATION

The diagnostic value of anamnesis and physical examination has as yet been insufficiently studied. Only pain distribution is considered to be a meaningful parameter from anamnesis.¹² The clinical test described most often for the LSR is the Lasègue test. If radicular pain can be elicited under 60°, there is a large chance that a lumbar herniated disc is present. However, the sensitivity of this test for the detection of LSR due to a herniated disc varies sharply: the global sensitivity is 0.91 with a specificity of 0.26.^{9,13} This specificity drops even more when the test is positive above 60°. The crossed Lasègue test is the only examination with good specificity (0.88), but this comes at the expense of the sensitivity (0.29).¹³ Both tests are described in Table 2.

There is no consensus about the specificity of the other neurological signs (paresis, sensory loss, or loss of

reflexes).¹² In practice, the presence of signs that are indicative of an L4 involvement (lessened patellar reflex, foot inversion) or an L5-S1 hernia (Achilles tendon reflex) are checked in a neurological examination. An L5 motor paresis will probably be characterized clinically by the “stomping foot,” decreased ankle dorsiflexion and/or extension of the toes and an S1 paresis due to a decrease in plantar flexion, among other things¹⁰ (Table 3).

In summary, a diagnosis of LSR appears to be justified if the patient reports radicular pain in one leg, combined with one or more positive neurological signs that indicate a nerve root irritation or neurological loss of function.¹⁴

I.C ADDITIONAL TESTS

Imaging Studies

Given that the natural course of lumbosacral radicular pain is favorable in 60% to 80% of patients and that the pain improves spontaneously or even disappears completely after 6 to 12 weeks, additional examination has little value in the acute phase.^{8,15} Medical imaging, primarily **magnetic resonance imaging (MRI)**, can confirm the presence of a herniated disc; this technique is preferred because of the better visualization of soft tissues and the lower radiation dose.¹⁴ The specificity of MRI and computer tomography (CT) is very low given that a herniated disc was identified by CT or **MRI in 20% to**

Table 2. Lasègue and Crossed Lasègue Test

The *Lasègue test* is performed by placing the patient in a supine position and having the patient lift up the affected leg (with a straight knee). The test is positive if this maneuver reproduces the symptoms. Rotation, abduction and adduction in the hip should be avoided, since these movements can have an effect on the result

The *crossed Lasègue test* is performed by a patient in the supine position lifting up the contralateral leg. The test is positive if lifting is accompanied by a pain reaction in the affected leg which follows the same pattern that appeared in the regular Lasègue test.

Table 3. Neurological Examination of the Lumbosacral Radicular Syndrome

Level	Pain	Sensory Loss Paresthesia	Motor Disturbances or Weakness	Disturbances in Reflexes
L3	Front of the thigh to the knee	medial portion thigh and knee	quadriceps femoris, iliopsoas, hip adductors	patellar reflex, adductor reflex
L4	Medial portion leg	medial portion leg	anterior tibialis, quadriceps, hip adductors	patellar reflex
L5	Lateral portion thigh and leg, dorsum of the foot	lateral portion leg, dorsum of foot, first toe	toe extensors and flexors, ankle dorsiflexors, eversion and inversion of the ankle, hip abductors	
S1	Posterior portion thigh, calf and heel	sole of the foot, lateral portion foot and ankle, two most lateral toes	gastrocnemius, biceps femoris, gluteus maximus, toe flexors	Achilles reflexes

36% of the asymptomatic population,¹⁶ and there is little correlation between the severity of a possible radiculopathy and the magnitude of the spinal disc herniation. Incidentally, the symptoms can disappear after a conservative therapy without a corresponding decrease in the volume of the herniated disc.¹⁷⁻¹⁹

In addition to this, a hernia could not be demonstrated on the scans of some patients with clinical symptoms of a radicular syndrome.^{20,21} In the event of an unclear clinical picture or in the absence of radiological arguments for radicular complaints, electromyography (EMG)/nerve conduction studies (NCS) can be performed to differentiate lumbar radicular syndrome from peripheral neuropathy (sensitivity 0.45 to 0.65).²² Other common causes of lumbar radicular pain, such as stenosis of the foramen intervertebrale, may be revealed by MRI or CT. Entrapment of the sciatic nerve such as piriformis syndrome is not included in this chapter.

Selective Segmental Nerve Blocks

Although the diagnostic nerve root block is a commonly used technique for determining the level of the radicular pain, there is uncertainty concerning its sensitivity and specificity. In a LSR without clear signs of a focal neurological deficit, there appears to have been a variable *hypoesthesia* already present in the majority of the patients before the execution of a diagnostic nerve root block.²³ These changes in sensory function can also vary in time and location.

With an intraforaminal block, there is also a real chance of a simultaneous block of the nervus sinuvertebralis. This nerve is responsible for the afferent input of the nearby disci intervertebrales (superficial annulus fibrosus), ligamentum longitudinale posterius, and the ventral dura mater and nerve root sleeve. In addition, the sensory fibers of the ramus dorsalis of the segmental nerve pass through the ganglion spinale (dorsal root ganglion, DRG) which is also blocked. This nerve innervates local back muscles and nearby facet joints. Furthermore, it is known that if the etiology of the pain is located proximally to a nerve block, this pain can be reduced by a peripheral nerve block. As a result, pain that originates from proximal spinal nerve root irritation with corresponding pain in the leg and back can in fact be influenced by a more peripheral block.²⁴ This was confirmed in a study by North²⁵ in which patients with radicular pain as their chief complaint had, in a randomized sequence, 4 different blocks with local

anesthetic. Paraspinal lumbosacral root blocks and medial branch posterior primary ramus blocks (at the same level or proximally) as well as nervus ischiadicus (sciatic nerve) blocks (collaterally or distal to the pathology) with 3 mL bupivacaine 0.5% provide a temporary greater pain reduction in the majority of cases, in comparison with a lumbar subcutaneous administration of the same product in an identical volume. The specificity of a single-level diagnostic block is further influenced by the injected volume, as 0.5 mL of contrast already reaches the adjacent level in 30% of cases, and 1.0 mL even in 67% of cases.²⁶ As a result, it appears that the specificity of diagnostic nerve root blocks is limited: a negative block has a specific predictive value, but isolated positive blocks are nonspecific.²⁷

An example of the variability of the effect of nerve root blocks in patients with LSR without neurological deficit is the incidence, location, and extent of the dermatomal areas with a *hypoesthesia*. Namely, the total area in which *hypoesthesia* can be found is very extensive, yet it is exceptional that in some patients, absolutely no *hypoesthesia* develops even though the technique performed is identical.²⁷ This pattern of *hypoesthesia* and radicular pain usually surpasses the boundaries of standard dermatomal charts, but is better understood if an overlap with the adjacent dermatomes is taken into account. The resulting adapted dermatomes are twice as large as those in standard dermatomal charts, but as a result, the sensory effects of diagnostic nerve root blocks lie more within the limits of the (adapted) dermatomal charts.²⁷

Conversely, the variability of *paresthesia* as a result of electro-stimulation appears to be much smaller; it is usually registered in the central sections of the standard dermatomes. The reproducibility of *paresthesia* by electro-stimulation also appears to be high: 80% of the *paresthesia* can be traced to within the borders of the standard dermatomal charts, and 98% to within the borders of the adapted dermatomal charts. In spite of this, the relationship to pain remains unclear. When pain is reported in an “adapted” dermatome, in only 1/3 of cases can a corresponding reduction in pain, *paresthesia*, and *hypoesthesia* be induced by electro-stimulation and nerve root blocks.

After a nerve root block, the average muscle force is reduced within the corresponding myotome, but the muscle force within the myotome is increased if the block has reduced the pain.²⁸ A possible explanation for the increase in muscle force in patients with a chronic

Table 4. Red Flags

First appearance of back complaints before 20th or after the 55th year
Trauma
Constant progressive back pain
Malignant disorder in the medical history
Long-term use of corticosteroids
Drug use, immunosuppression, HIV
(Frequent) general malaise
Unexplained weight loss
Structural deformities of the spinal column
Infectious disorders (eg, herpes zoster, epidural abscess, HIV, Lyme disease)
Neurological loss of function (motor weakness, sensory disturbances, and/or micturition disturbances)

lumbar radicular syndrome is the finding that pain has an inhibiting effect on the muscle force (diffuse noxious inhibitory control or DNIC).²⁹ After pain reduction, the inhibition lessens which results in a normalization of the muscle force.³⁰

In practice, the most rational method used to confirm the suspected level of radicular complaints is still the use of one or more selective diagnostic blocks. These selective infiltrations must occur with a limited amount of local anesthetic (max. 1 mL) per level and in separate sessions.

I.D DIFFERENTIAL DIAGNOSIS

In cases of acute low back pain, physical abnormalities, which can account for the complaints, are ruled out first on the basis of the so-called “red flags”; yet in cases of chronic low back pain, we recommend also checking whether there are signs which could indicate underlying pathology such as tumors and infections, among others (Table 4). When making a differential diagnosis, inflammatory/metabolic causes (diabetes, ankylosing spondylitis, Paget’s disease, arachnoiditis, sarcoidosis) must also be taken into account; these must be ruled out first.¹⁰

The acute *cauda equina syndrome* is usually the result of a large, central disc herniation with compression of the low lumbar and sacral nerve roots, usually at the L4-L5 level. As a result of the sacral polyradiculopathy, a significant bowel and micturition dysfunction can arise with a characteristic saddle anesthesia. If the lumbar nerve roots are also involved, this leads to weakness in the legs that can possibly lead to paraplegia. Rapid recognition of these symptoms and referral for emergency surgery is recommended.¹⁰

II. TREATMENT OPTIONS

II.A CONSERVATIVE MANAGEMENT

(Sub)Acute Radicular Complaints

Controversy exists concerning the conservative approach to LSR since there is no strong evidence of the effectiveness of most treatments.³¹ Providing adequate information to the patient about the causes and prognosis of LSR can be a logical step in the management of this problem, but this has not yet been studied in randomized, controlled studies.¹⁴

There is no difference between the advice for *bed rest* when compared with the advice to *remain active*.³²

The use of *Non-Steroidal Anti-Inflammatory Drugs* or *Cox-2 inhibitors* can have a significant effect on acute radicular pain compared with placebo.^{33,34} There are however no long-term results on the evolution of LRS.

Exercise therapy can possibly have a beneficial effect. For this reason, it is often considered a first-line treatment. However, until now, evidential value for this is lacking.^{12,31} A randomized study was able to demonstrate a better outcome after 52 weeks in patients who received physiotherapy in the form of exercise therapy combined with a conservative therapy from the general practitioner in comparison with patients who received only the conservative therapy (79% versus 56% Global Perceived Effect, respectively). However, this does not appear to be cost-effective.³⁵ For a selected population, a surgical intervention results in a more rapid lessening of the acute radicular complaints in comparison with a conservative approach, but the outcomes after 1 to 2 years are equivalent.^{36–38} Furthermore, the effect of surgery on the natural course of the herniated disc disease is unclear and there are no proven arguments for an optimal time period for surgery.³⁹

For patients with a neurological loss of function due to a herniated disc, immediate surgical treatment is usually recommended. From the available studies, it appears that this loss of function remains steady initially, but after surgery it can still regress (up to 50% of the patients).^{40,41} It can therefore be stated that the outcome in cases of herniated disc with regard to neurological loss of function is determined by the severity of the lesion at the outset and not by whether an intervention occurs sooner or later.⁴²

In patients with a spinal canal stenosis with secondary neurological loss of function on which surgery has been performed, reflex disturbances and sensory and motor deficits will be permanent or will only very slowly

be partially restored. Up to 70% of the patients will continue to have residual neurological abnormalities after decompression⁴³ and the risk of permanent neuropathy is larger in central spinal canal stenosis in comparison with lateral spinal canal stenosis.⁴⁴

Chronic Radicular Complaints

The place of physiotherapy in these cases is also unclear, since there are no randomized studies available.⁴⁵ For chronic LSR, a trial period with medication is indicated. Classically, neuropathic pain is treated by prescribing *tricyclic antidepressants* (TCAs) such as amitriptyline.⁴⁶ Although a medicinal treatment policy is still in the foreground, in practice, this is not always evident. Thus, for these neurogenic conditions, less than 1/3 of the patients will experience a reduction in pain that is better than “moderate”.⁴⁶ Furthermore, various reviews were performed concerning the place of the TCAs⁴⁷ and anti-convulsants^{6,46} in the treatment of neuropathic pain. It is striking that the included studies were mostly performed in patients with diabetic neuropathy and postherpetic neuralgia. The extension of these results to patients with LRS, with a physiopathology based more on compression and inflammation of the nerve root and the ganglion spinale (DRG) has not yet been scientifically proven.⁵

Anticonvulsants are a possible alternative for the treatment of neuropathic pain if tricyclic antidepressants cannot be tolerated or are contraindicated. Gabapentin has been studied most often in this indication and is supported by a randomized controlled trial (RCT).⁴⁸ The results are variable and optimization of the dosage is frequently hindered by side effects. The role of opioids in the treatment of neuropathic pain has long been considered controversial. Recent guidelines concerning the treatment of neuropathic pain mention tramadol and oxycodone as possible therapeutic options.⁶ In an open-label trial using transdermal fentanyl in 18 patients with radicular pain, an average pain reduction of 32% was achieved.⁴⁹

II.B INTERVENTIONAL MANAGEMENT

Anesthesiological treatment techniques are indicated for patients with radicular pain. Epidural administration of corticosteroids is generally indicated in cases of subacute radicular pain. In patients with chronic radicular complaints, corticosteroids will not provide any improvement in the outcome in comparison with local anesthetics alone. This indicates that epidural corticosteroids are more effective for (sub)acute radicular pain

where a significant inflammatory pain component is present.⁵⁰ (Pulsed) radiofrequency (PRF) treatment is a treatment option for chronic radicular pain.

Epidural Corticosteroid Administration

The logic of epidural corticosteroid administration rests on the anti-inflammatory effect of the corticosteroids, which are administered directly onto the inflamed nerve root. There are three approaches: interlaminar, transforaminal, and caudal.

Interlaminar Corticosteroids. The available evidence concerning interlaminar corticosteroid administration has been studied in systematic reviews. The conclusions of these reviews are divergent depending on the chosen evaluation parameters. McQuay and Moore calculated the Number Needed to Treat (NNT). To achieve 50% pain reduction in the short term (1 day to 3 months), an NNT of 3 is obtained and an NNT of 13 for long-term pain relief (3 months to 1 year).⁵¹ A systematic review of RCTs concluded that there is insufficient proof of the efficacy of this technique. If there are benefits, then they are of short duration.⁵² A recent systematic review of RCTs showed that among the 11 RCTs of interlaminar steroid injection for radiculopathy, four trials are rated high quality.⁵³ Three of the four trials used ligamentum interspinale (interspinous ligament) saline injection as control intervention. All three trials showed positive results for short-term benefits (≤ 1 months).⁵⁴⁻⁵⁶ The other trial used epidural saline injection as control and did not show any benefit.⁵⁷

Transforaminal Corticosteroids. The variable results of corticosteroids administered interlaminarly are ascribed to the fact that there is no certainty that the needle reaches the epidural space and even if it did, there is no certainty that the medication reaches the ventral section of the epidural space.⁵⁸ Transforaminal administration allows a more precise application of the corticosteroids at the level of the inflamed nerve root. Three high quality, placebo controlled trials evaluating transforaminal approach reported mixed results.⁵³ One showed long-term benefits in one year,⁵⁹ one showed mixed short-term benefits,⁶⁰ and one showed no benefit.⁵⁰

In a double-blind, randomized study, patients who were scheduled for surgical intervention received an epidural injection with local anesthetic only or local anesthetic with corticosteroid *at random*. By the follow-up (13 to 28 months), 20/28 patients in the local anesthetic

with corticosteroid group had decided not to undergo surgery, while in the local anesthetic only group, 9/27 decided to forego a surgical intervention.⁵⁹ The majority (81%) of the patients who had not yet had surgery 1 year after infiltration were able to avoid the operation after 5 years.⁶¹ There was no statistical difference between the treatment groups.

A prospective controlled study of transforaminal epidural corticosteroids showed superiority of this procedure over trigger-point injection in patients with disc herniation.⁶² Karpinnen's group⁶⁰ carried out a randomized, controlled study in patients with radicular pain and disc herniation documented by MRI, in which the transforaminal administration of local anesthetic with corticosteroid was compared with transforaminal injections of normal saline solution. Two weeks after the treatment, the clinical result in the corticosteroid group was better than that of the group treated with normal saline solution. After 3 to 6 months, on the other hand, patients in the group with normal saline were in better condition owing to a rebound effect that was noted in the corticosteroid group. A subanalysis in which the results of patients with a "contained" herniation were compared with those of patients with an "extruded" herniation showed that in the first group, corticosteroid injections were superior to placebo while in the group with "extruded" herniation, the opposite was found.⁶³ In this study, "contained herniation" was defined as a herniation with a broad base, which is still contained within the ligamentum longitudinale posterius. "Extruded herniation" is a herniation that breaks through the ligamentum longitudinale posterius.

In a comparative study, the effectiveness of caudal, interlaminar, and transforaminal corticosteroid administration in the epidural space was compared in patients with radicular pain as a result of disc herniation. The transforaminal approach gave the best clinical results.⁶⁴ A double-blind, randomized study compared the efficacy of interlaminar and transforaminal corticosteroid administration in patients with lumbar radicular pain as a result of CT- or MRI-confirmed herniated disc that lasted less than 30 days. Six months after the treatment, the results in the transforaminal-treatment group was significantly better than that of the group that was treated interlaminarly in the areas of pain reduction, daily activity, free-time and work activities, and anxiety and depression.⁶⁵

Caudal Corticosteroids. Four placebo-controlled trials were conducted, but none were rated high quality.⁵³

The results are mixed and no definitive conclusions can be drawn from these studies.

In summary, one can state that the **transforaminal epidural corticosteroid administration is preferable**. In practice, due to the not-yet-completely elucidated, rare neurological complications associated with the transforaminal administration route, the interlaminar and caudal approaches can also still be considered.

PRF

The application of conventional RF treatment (at 67°C) adjacent to the lumbar ganglion spinale (DRG) has lost interest because no extra value could be shown in comparison with a sham procedure in a randomized, double-blind, sham-controlled study.⁶⁶

PRF treatment adjacent to the lumbar ganglion spinale (DRG) was studied in a retrospective study. In a group of 13 patients for which a surgical intervention was planned, the PRF treatment adjacent to the ganglion spinale (DRG) of the nerve involved precluded the intervention in 11 patients. One patient had a disc operation and 1 underwent a spinal fusion 1 year after the treatment without having radicular pain at the time of the operation.⁶⁷ In another retrospective study, PRF treatments were carried out in patients with a radicular syndrome as a result of disc herniation, spinal canal stenosis, or failed back surgery syndrome (FBSS). A significant reduction in pain and in analgesic consumption was attained in the patients with a disc herniation (NNT: 1.38) and spinal canal stenosis (NNT: 1.19), but not in those with FBSS (NNT: 6.5).⁶⁸ An RCT aimed at identifying the potential additional effect of a conventional RF treatment directly after a PRF treatment adjacent to the lumbar ganglion spinale (DRG). Thirty-seven patients were treated with PRF and 39 patients with PRF and RF. A marked decrease in VAS pain score was observed in both groups, but no significant difference between groups in pain reduction and duration of action could be identified.⁶⁹

Adhesiolysis and Epiduroscopy

The goal of lysis of epidural adhesions is to remove barriers in the epidural space that may contribute to pain generation and prevent delivery of pain relieving drugs to target sites.

The development of a navigable, radio-opaque, kink-resistant, soft-tipped catheter has allowed placement at or near this target site in most patients. In the literature, adhesiolysis with or without endoscopic control is sometimes assessed together. There are 2 RCTs on

fluoroscopic-guided adhesiolysis. Patients included in the RCTs suffered chronic low back pain and sciatica and might have undergone previous back surgery, furthermore the treatment protocols differed. Heavner et al.⁷⁰ compared the effect of mechanical adhesiolysis with (1) a combination of hyaluronidase and hypertonic saline; (2) hypertonic saline solution; (3) isotonic saline solution; and (4) hyaluronidase and isotonic saline solution. The treatment consisted of a 3-day procedure where the catheter was inserted and the drugs were injected on three consecutive days. Manchikanti et al.⁷¹ assessed a one-day procedure in 3 patient groups: a control group treated with injection of local anesthetic corticosteroid and normal saline without adhesiolysis; the second group consisting of patients undergoing adhesiolysis, with injection of local anesthetic, steroid, and normal saline; and the third group consisting of patients undergoing adhesiolysis, with an injection of 10% sodium chloride solution, in addition to local anesthetic and steroid. The third trial compared the effect of adhesiolysis and injection of corticosteroid and local anesthetic followed, 30 minutes later, by an injection of hypertonic saline (10%) with conservative treatment.⁷² These trials and all the observational trials but one found positive short- and long-term outcome. The trial on the effect of adhesiolysis with hypertonic saline found only short-term positive outcome.⁷³

Epiduroscopy, which is also called spinal endoscopy, is an alternative way to perform adhesiolysis under visual control. It couples the possibility of diagnostic and therapeutic interventions in one session. This technique was evaluated in 2 systematic reviews.^{74,75} A prospective randomized trial showed significant improvement without adverse effects in 80% of the patients receiving epiduroscopy at 3 months, 56% at 6 months, and 48% at 12 months, compared with 33% of the patients in the control group showing improvement at one month and none thereafter.⁷⁶ In an RCT, 60 patients with a 6-to-18-month history of sciatica received either targeted epidural local anesthetic and steroid placement with manipulation of the adhesions using a spinal endoscope or caudal epidural local anesthetic and steroid treatment. No significant differences were found between the groups for any of the measures at any time.⁷⁷ Observational studies showed good short- and long-term pain relief.⁷⁸⁻⁸³

Spinal Cord Stimulation in FBSS

FBSS is a persistent back pain that may or may not include pain radiating to the leg after one or more back

operations. Spinal cord stimulation (SCS) consists of the percutaneous application of electrodes at the level of the spinal cord segment involved. These electrodes are then connected to a generator that delivers electrical pulses to stimulate the painful dermatome and to induce altered pain conductivity, transmissibility, and perception. A systematic review of the effectiveness of SCS for the treatment of chronic low back and leg pain in patients with FBSS included an RCT, a cohort study and 72 case reports. The RCT demonstrated clear advantage of SCS in comparison with repeat surgery. However, the results of the case reports are very heterogeneous.⁸⁴ A randomized study that compared SCS with conventional treatment in FBSS patients showed that fewer patients from the SCS group switched over to conventional treatment than did patients who initially received a conventional treatment and then switched over to SCS. The number of patients satisfied with the treatment was higher in the SCS group.⁸⁵

II.C COMPLICATIONS OF INTERVENTIONAL MANAGEMENT

Complications and Side Effects of Epidural Corticosteroids

Interlaminar Epidural Corticosteroids. The most frequent side effect is a dural puncture (2.5%) with or without a transient headache (2.3%).⁸⁶ Minor side effects, such as transient increase in complaints or the appearance of new neurological symptoms more than 24 hours after the infiltration, occur in 4% of the patients; the median duration of the complaints was 3 days (1–20 days).⁸⁷ In a study examining side effects in 4,722 infiltrations with betamethasone dipropionate and betamethasone sodium phosphate, 14 (0.7%) serious side effects were reported (cardiovascular, gastrointestinal, allergy), 7 of which were attributed to the product.⁸⁸ More serious complications are cases of aseptic meningitis, arachnoiditis, and conus medullaris syndrome, but these typically occur after multiple accidental subarachnoid injections. Two cases of epidural abscess, 1 case of bacterial meningitis, and 1 case of aseptic meningitis were also reported.⁸⁹

Transforaminal Epidural Corticosteroids. At the time of preparing this manuscript, 7 publications report 9 cases of neurological complications such as paraplegia following lumbar transforaminal epidural corticosteroid administration.⁹⁰⁻⁹⁶ The probable mechanism is an injury to an unusually low dominant radiculomedullary

artery.⁹⁰ The largest radicular artery is the arteria radicularis magna (artery of Adamkiewicz); in 80% of the population, this artery is present in the spinal canal between T9 and L1. However, in a minority of cases, it can occur between T7 and L4, which results in the possibility that the artery is in the vicinity of the end position of the needle in a transforaminal infiltration. Depot injections can then mimic an embolism; if this occurs in a critical artery which supplies the anterior spinal artery, spinal cord ischemia may result.⁹⁷ Of the reported cases of neurologic complications, 1 occurred after Th12-L1, 1 case at L1-L2, 2 cases at L2-L3, 3 cases at L3-L4, 1 after simultaneous L3-L4 and L4-L5 injection, and finally, 1 case after an S1 injection.

A retroperitoneal hematoma was reported in a patient having anticoagulant therapy who received a transforaminal injection.⁶⁰ Two cases of dural puncture,⁹⁸ one disc entry,⁹⁹ one case of cauda equina¹⁰⁰ and one case of transient blindness attributed to the temporarily intra-epidural pressure increase.¹⁰¹ Infectious complications such as epidural abscess caused by MRSA (1 case),¹⁰² discitis (1 case)¹⁰³ and one case of vertebral osteomyelitis¹⁰⁴ are reported.

The recently reported cases of serious complication with the transforaminal approach warrant a cautious policy. It is recommended to only perform transforaminal infiltrations under the L3 level and to always administer the injection fluid during real-time imaging, the additional use of digital subtraction angiography may be of value. It is also recommended to first administer a test dosage of local anesthetic before infiltrating the depot corticosteroid after waiting 1 to 2 minutes to observe potential neurologic signs.¹⁰⁵ Neurological complications rarely occur when using the correct technique and when sedation is avoided. If a significant increase in pain is reported during the injection of contrast agent, local anesthetic and/or corticosteroids, the procedure must be immediately stopped in order to ascertain the cause of the pain.

Endocrine Side Effects. Cushing's syndrome was reported in the prospective study of the side effects of epidurally administered betamethasone dipropionate and betamethasone sodium phosphate.⁸⁸

Side Effects and Complications of RF Treatments

Conventional RF Treatment. A burning pain was found to occur in 60% of RF-treated patients, and a hyposensitivity in the associated dermatome in 35% of

RF-treated patients.¹⁰⁶ These side effects disappeared spontaneously after 6 weeks. However, in a later study, there was no difference in side effects and complications between a classic RF group and a sham group.⁶⁶

PRF Treatment. In an extensive review of the literature on the use of PRF covering over 1,200 patients no neurological complication was identified.¹⁰⁷ Twelve publications are currently available regarding PRF treatment adjacent to the ganglion spinale (DRG). Eight of those publications specifically report PRF treatment adjacent to the lumbar ganglion spinale (DRG).^{67-69,108-112} In total information on 295 PRF procedures is listed and no side-effects or complications are mentioned.

Side Effects and Complications of Epidural Adhesiolysis and Epiduroscopy

Four studies look specifically into the complications of epidural adhesiolysis.¹¹³⁻¹¹⁶ The most commonly reported complications of percutaneous adhesiolysis are dural puncture, catheter shearing, and infection. Other potential complications include intravascular injection, vascular injury, cerebral vascular or pulmonary embolus, reaction to the steroids, hypertonic saline, or hyaluronidase, and administration of high volumes of fluids potentially, resulting in excessive epidural hydrostatic pressures, brain damage, and death.

Talu and Erdine¹¹³ reviewed percutaneous adhesiolysis complications in 250 patients. Three patients (1.2%) developed epidural abscesses, and 1 patient developed a severe headache. Retained sheared adhesiolysis catheter was described in a patient who underwent percutaneous adhesiolysis to treat persistent back and leg pain after 2 previous lumbar surgeries.¹¹⁴

Unintended subarachnoid or subdural puncture with injection of local anesthetic or hypertonic saline is one of the major complications of the procedure with catheter adhesiolysis.

For epiduroscopy, side effects and complications are comparable to those of adhesiolysis without endoscopic control. There is however an additional potential of increased pressure in the epidural space due to the continuous pressurized liquid injection, necessary to obtain a clear image. Up till now, only one report of visual disturbances due to increased liquor pressure has been reported. Careful monitoring of pressure fluctuations is warranted to reduce the risk of prolonged increased liquor pressure and the duration of the procedure should be limited to maximum 60 minutes.

Table 5. Summary of the Evidence for Interventional Management

Technique	Assessment
Interlaminar corticosteroid administration	2 B±
Transforaminal corticosteroid administration in “contained herniation”	2 B+
Transforaminal corticosteroid administration in “extruded herniation”	2 B–
Radiofrequency lesioning at the level of the spinal ganglion (DRG)	2 A–
Pulsed radiofrequency treatment at the level of the spinal ganglion	2 C+
Spinal cord stimulation (FBSS only)	2 A+
Adhesiolysis—epiduroscopy	2 B±

Side Effects and Complications of SCS

In a review of the complications of SCS, 18 studies on 112 patients receiving SCS for FBSS were identified. Forty-eight patients (42%) reported a side effect or complication. Complications can be subdivided in: technical, biological (postoperative), and others. The majority (> 25%) of the complications are of technical order such as lead migration, lead breakage, hardware malfunction, battery failure, and loose connection. Postsurgical complications can be infection, cerebrospinal fluid leakage, and hematoma. Undesirable stimulation, pain over the implant, skin erosion, and allergy have also been reported.¹¹⁷

II.D EVIDENCE FOR INTERVENTIONAL MANAGEMENT

The summary of the evidence for interventional management of lumbosacral radicular pain is given in Table 5.

III. RECOMMENDATIONS

Based on the evidence available regarding effects and complications, we recommend the following techniques for the treatment of LRS:

- Since **epidural corticosteroid injections** have mainly short-term effects; these techniques are recommended for patients with **subacute radicular pain symptoms**.
- In patients with pain at the **lumbosacral level (L4, L5, S1)** as a result of a “**contained herniation,**” a **transforaminal epidural** injection with local anesthetic and corticosteroids is recommended. A preference seems to exist for transfo-

raminal epidural corticosteroid administration over caudal and interlaminar corticosteroids below level L3.

- RF treatment adjacent to the ganglion spinale (DRG) is not recommended. A PRF treatment adjacent to the ganglion spinale (DRG) can be considered.
- Spinal cord stimulation is recommended for patients with a therapy-resistant radicular syndrome, but only in specialized centers.
- Epiduroscopy and adhesiolysis can be considered in the context of research and only in specialized centers.

III.A CLINICAL PRACTICE ALGORITHM

Figure 1 represents the treatment algorithm based on the available evidence.

III.B TECHNIQUES

Practical Recommendations Epidural Corticosteroid Administration

There are 7 systematic reviews concerning epidural corticosteroid administration for the treatment of LRS. With regard to short-term effectiveness, 6 of the 7 systematic reviews give a positive assessment and 1 gives a negative assessment (conflicting evidence).^{86,118–122} There are no comparative studies available for the effectiveness and/or complications of the various depot corticosteroids, which means that a distinction between these products cannot be verified.

It is possible that the particle size of the depot corticosteroid is related to the reported neurological complications, but the literature concerning this possibility is also inconclusive.¹²³ Up till now, no reported neurologic complications were noted with the nonparticulate corticosteroid dexamethasone. One abstract has prospectively compared the transforaminal use of triamcinolone with dexamethasone in 50 patients.¹²⁴ A significant greater reduction in pain was noted after 2 weeks in patients treated with triamcinolone, so this far evidence about its efficacy at the lumbar level is lacking. Currently, there is no evidence that a higher corticosteroid dosage produces a better clinical effect,¹²⁵ yet the risk of endocrine side effects is substantially higher. It is for this reason that the lowest dosage of depot corticosteroid is currently recommended.

With regard to the number of infiltrations, there are no comparative studies that have shown that the systematic implementation of 3 infiltrations would result in

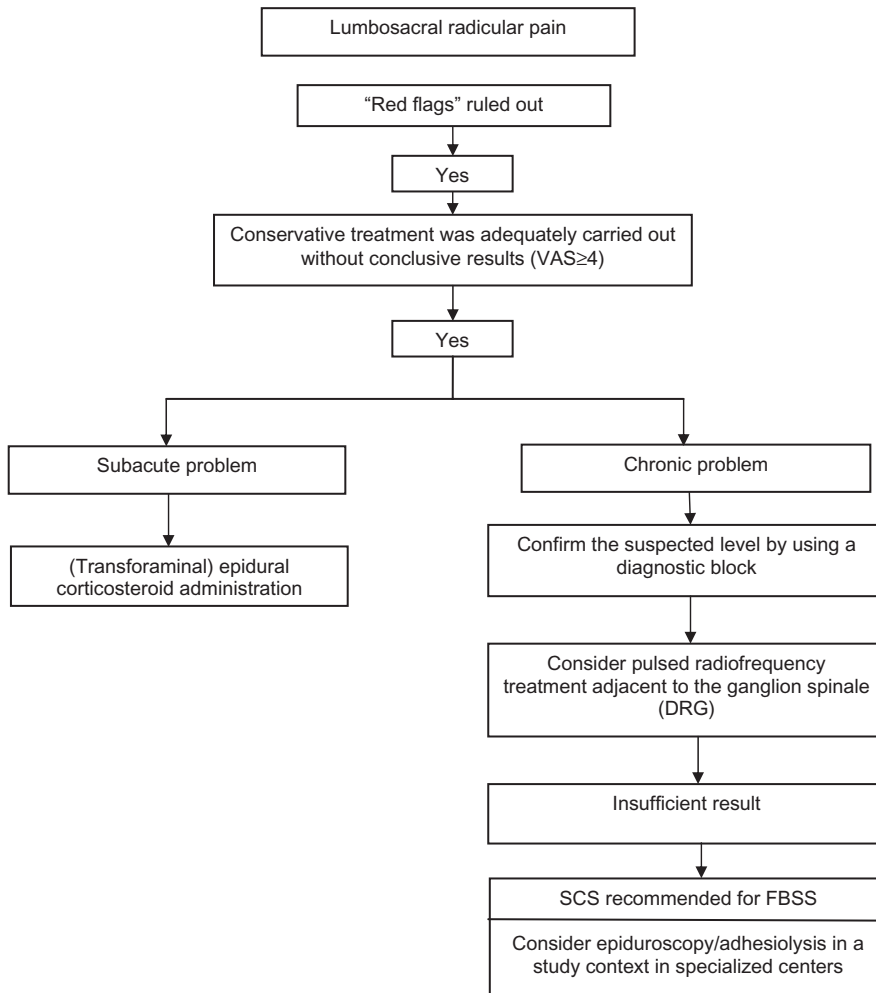


Figure 1. Practice algorithm for the treatment of lumbosacral radicular syndrome.

superior outcome.¹²⁶ From the RCTs available concerning the transforaminal administration of corticosteroids, one finds an average of 1 to 2 infiltrations. Considering the potential endocrine side effects, adhering to an interval of at least 2 weeks between two infiltrations is recommended.

Interlaminar Epidural Corticosteroid Administration

This technique can be carried out with the patient in a prone position, lying on the side or sitting; in the two latter postures, place the patient in flexion or in the “fetal” position.¹²⁷ The sitting posture is considered to be the most comfortable for the patient as well as for the pain physician. This position allows a correct assessment of the midline and avoids the rotation of a lateral decubitus position.

Determination of the correct level can occur with reference to the cresta iliaca (iliac crest) or via fluoroscopy. In the *medial approach*, first a local anesthetic will

be infiltrated in the middle of the processus spinosi, thereafter, the subcutaneous tissue and the ligamentum supraspinosi are approached with an epidural needle. The latter offers enough resistance that the epidural needle remains in position when the needle is released. Subsequently, the needle enters the ligamentum interspinale and the ligamentum flavum, which both provide additional resistance. A false sensation of loss of resistance may occur upon entering the space between the ligamentum interspinale and the ligamentum flavum. The ligamentum flavum provides the greatest resistance to the epidural needle since it is almost entirely composed of collagenous fibers. Breaking through this ligament to the epidural space is accompanied by a significant loss of resistance. When injecting medication into the epidural space, normally no resistance should be felt since it is filled with fat, blood vessels, lymph tissue and connective tissue. The epidural space is 5 to 6 mm wide at the L2-L3 level in a patient in a flexion

position. In addition, the injection of contrast agent can verify the correct positioning in the epidural space.

In the case of aspiration of blood, the needle must be reoriented; in the case of aspiration of cerebrospinal fluid, the procedure must be repeated at another level. In the latter case, an overflow to the cerebrospinal fluid is possible; therefore, this procedure must be carried out with caution.

Classically, an infiltration consists of an injection of a local anesthetic with a corticosteroid. There is a tendency to perform this procedure under fluoroscopy, yet thus far, no advantages of fluoroscopic control have been demonstrated.^{128,129}

Transforaminal Epidural Corticosteroid Administration

In a transforaminal approach, the C-arm is adjusted in such a way that the X-rays run parallel to the cover plates of the relevant level. Thereafter, the C-arm is rotated until the processus spinosus projects over the contralateral facet column. With the C-arm in this projection, the injection point is found by projecting a metal ruler over the medial part of the foramen intervertebrale. If there is a superposition of the processus articularis superior (superior articular process) of the underlying joint, the C-arm must be rotated cranially.

A 10-cm long, 25-G or 22-G needle with connection tubing that is first flushed with contrast medium is inserted here locally in the direction of the radiation beam. Thereafter, the direction is corrected such that the needle is projected as a point on the screen (Figure 2). Then, in a lateral view, the depth of the needle tip is checked. A classical approach is in the dorsocranial quadrant, care should be taken that no arterial/venous flow is noticed during real time imaging of contrast injection. We recommend avoiding that the needle elicits paresthesia in the patient. Paresthesia is considered unpleasant by the patient and, in addition, segmental medullary blood vessels may be hit.^{91,130} Therefore, the "safe triangle" should be taken into account (Figure 3). This triangle is formed cranially by the underside of the upper pediculus, laterally by a line between the lateral edges of the upper and lower pediculus and medially by the spinal nerve root (as the tangential base of the triangle). This is considered to be a safe zone; if a radiating pain still occurs during the procedure, the needle must be pulled back several millimeters.

The direction of the radiation beam is now modified to forward-backward (A-P view); as a result, the point of the needle should be located between the lateral edge

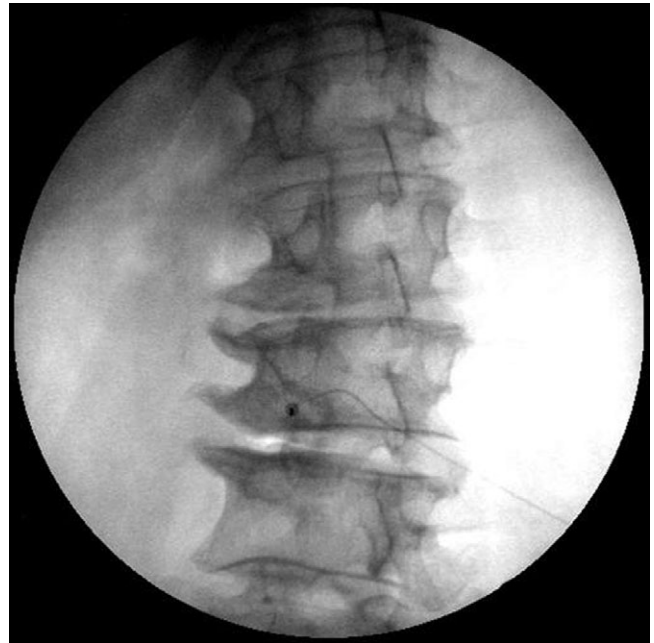

Figure 2. Lumbar transforaminal epidural injection: injection point (oblique insertion).

and the middle of the facet column. After the injection of a small quantity of contrast agent during real-time imaging, the course of the ramus anterior (spinal nerve), in the epidural or laterocaudal direction becomes visible. If this image is not attained due to a position that is too lateral, the needle must be more deeply inserted toward the ganglion spinale (DRG). The execution of this procedure during real-time imaging allows the distinction to be made between an accidental intrathecal, intra-arterial or intravenous injection.

After a correct visualization of the ramus anterior (spinal nerve), a test is carried out with 1 mL bupivacaine 0.5% or xylocaine, 1 to 2 minutes thereafter, the patient is asked to move the legs to rule out a sudden paresthesia based on medullary ischemia.^{91,97} The corticosteroid dosage can then be injected.

S1 Transforaminal Epidural Procedure

The technique used at the S1 level is analogous with that used for the lumbar levels; however, this time the needle is positioned through the foramen sacrale dorsale of S1 on the S1 pedicle. For this, the target lies on the caudal edge of the S1 pediculus on a location homologous to that in the case of the lumbar transforaminal infiltrations. Radiologically, this foramen cannot be that clearly distinguished, but by reorienting the C-arm cephalo-caudally and rotating it ipsilaterally, one can

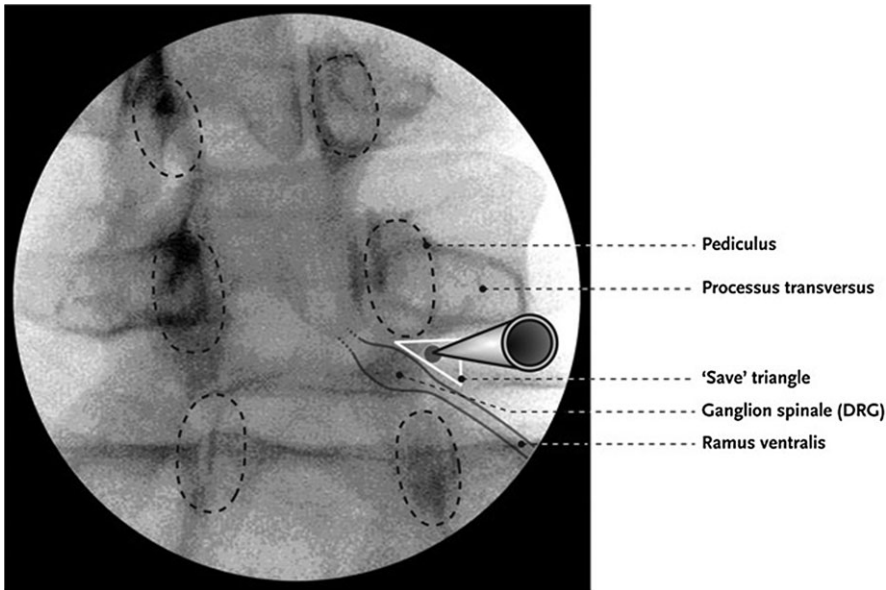


Figure 3. "Safe triangle" for the insertion of the needle in transforaminal epidural injection (illustration: Rogier Trompert Medical Art. <http://www.medical-art.nl>).

cause the foramen sacrale ventrale and the foramen sacrale dorsale of S1 to overlap. The puncture point is chosen at the level of the lateral edge of the dorsal sacral foramen of S1. In an optimal position, the needle point is positioned at 5 mm from the floor of the canalis sacralis in a lateral view.

PRF Treatment

Diagnostic Block. In a diagnostic block, the C-arm is adjusted in such a way that the X-rays run parallel to the end plates of the relevant level. Thereafter, the C-arm is rotated until the processus spinosus projects over the contralateral facet column. With the C-arm in this projection, the injection point is found by projecting a metal ruler over the *lateral part* of the foramen intervertebrale. A 10-cm long, 22-G needle is inserted here locally in the direction of the rays. Thereafter, the direction is corrected such that the needle is projected as a point on the screen (Figure 4). The direction of the radiation beam is now modified to a profile (lateral) view, and the needle inserted until the point is located in the craniodorsal part of the foramen intervertebrale (Figure 5).

In an AP view, the course of a small amount of contrast agent is followed with "real-time imaging"; it spreads out laterocaudally along the spinal nerve (Figure 6). Finally, a maximum of 1 mL lidocaine 2% or bupivacaine 0.5% is injected.

A prognostic block is considered positive if there is a 50% reduction in symptoms 20 to 30 minutes after the

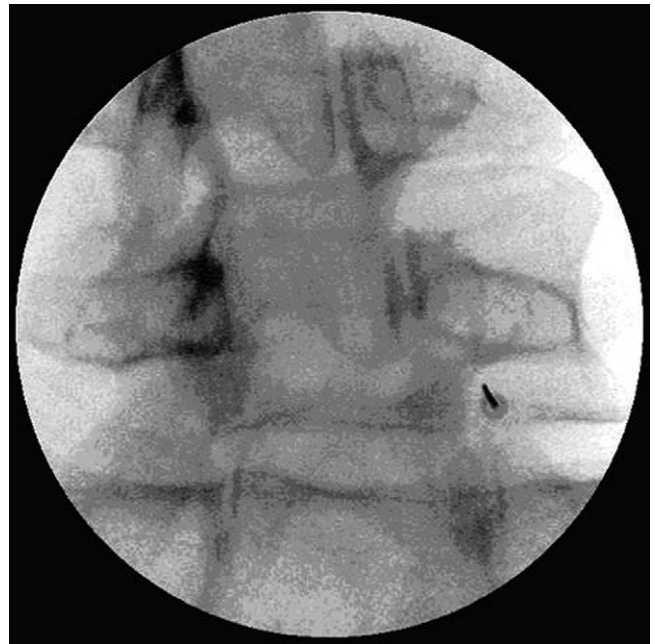


Figure 4. Lumbar DRG: oblique insertion.

intervention. The level that best satisfies the aforementioned criteria is chosen for PRF treatment.

Lumbar Percutaneous PRF. The insertion point for PRF treatment is determined in the same way as for the diagnostic block; this time, the projection is kept as *medial* as possible in order to maximally reach the ganglion spinale (DRG). The cannula is inserted in the

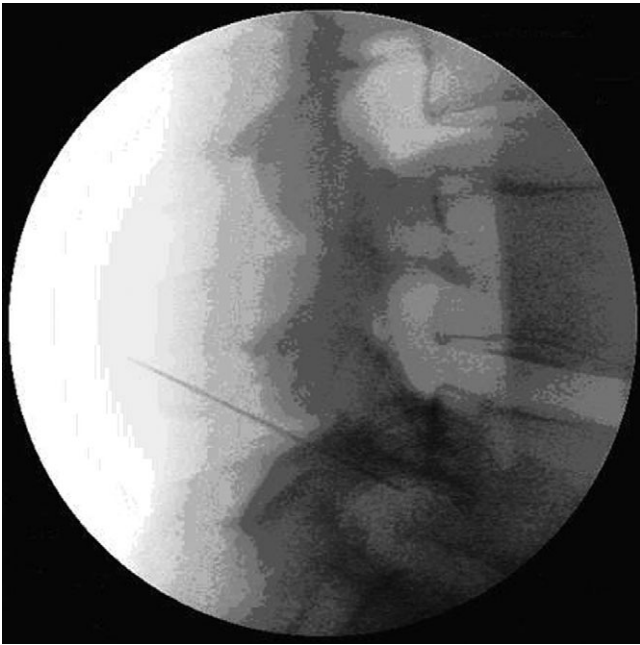

Figure 5. Lumbar DRG lateral insertion.

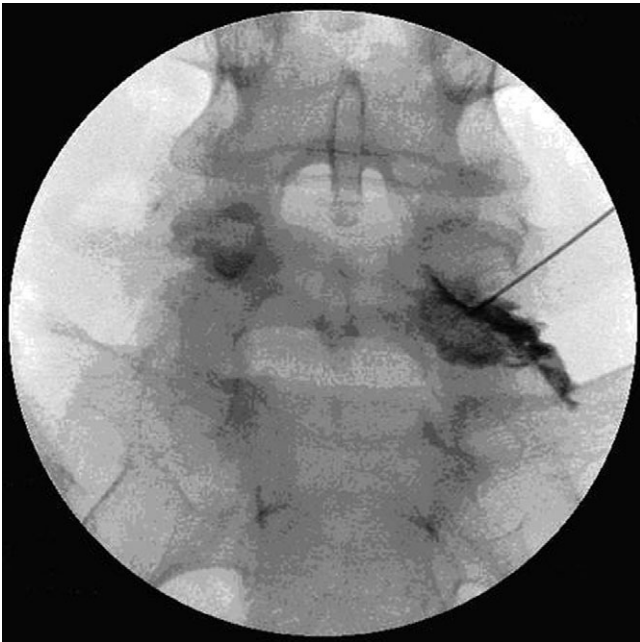

Figure 6. Lumbar DRG: spread of contrast fluid along the segmental nerve.

direction of the radiation beam. While the cannula is still located in the superficial layers, the direction is corrected so that the cannula is projected as a point on the screen. Thereafter, the cannula is carefully inserted

further until the point is located in the middle on the foramen intervertebrale in lateral view.

The stylet is removed and exchanged for the RF probe. The impedance is checked, and thereafter, stimulation at 50 Hz is done. The patient should now feel tingling at a voltage of < 0.5 V.

If these criteria are met, the position of the cannula is recorded in two directions on a video printer. Thereafter, a pulsed current (routinely 20 ms current and 480 ms without current) is applied for 120 s with an output of 45 V; during this procedure, the temperature at the tip of the electrode may not surpass 42°C. The output may need to be reduced.

The target is an impedance of less than 500 Ω . If it is higher, fluid injection can reduce this value. There are reports that the injection of a contrast agent can paradoxically increase the impedance. After repositioning, one can search for a lower stimulation threshold for additional treatment.

Adhesiolysis.¹³¹ Under fluoroscopic control the target level is identified. The C-arm is then rotated 15 to 20° oblique to the ipsilateral side of the targeted foramen intervertebrale. Once a “Scotty dog” image is obtained, the fluoroscope is rotated in a caudal-cephalad direction for 15 to 20°. A caudal-cephalad rotation elongates the superior articular process (“ear of the Scotty dog”). The tip of the ear, or superior articular process, in the “gun barrel” technique is marked on the skin as entry point. An 18-G needle is used to make a puncture wound. Through this wound, a 16-G Epimed R-K epidural needle is advanced anteriorly until bone is contacted. A lateral fluoroscopic image is obtained before further introduction of the needle. To facilitate passage of the needle past the articular process, the epidural needle is turned laterally to slide past the bone and stop just after a “pop” is felt. The needle tip on a lateral view should be in the posterior aspect of the foramen. An Epimed Tun-L-XL epidural catheter is then inserted through the epidural needle. Occasionally, the epidural needle must be tilted at the hub laterally to aid entry of the epidural catheter into the anterior epidural space. The catheter is advanced medial to the pedicle. After catheter placement is confirmed to be in the anterior epidural space under anteroposterior and lateral views, the stylet is removed from the catheter and a connector is placed on the proximal end of the epidural catheter.

Aspiration should be negative before 3 mL radiographic contrast is injected. The contrast injection

should show opening of the entered neuroforamen, with contrast exiting along the path of the nerve root.

Lysis is commonly performed with hypertonic saline but remains controversial due to its potential neurotoxicity should intrathecal spread occur.

After performing the lysis, local anesthetic and corticosteroid is injected.

When performing adhesiolysis according to the Racz procedure, the catheter is kept in place and lysis is repeated on 3 consecutive days.¹³² Manchikanti on the other hand advocates a one-day procedure.¹³³

Epiduroscopy.⁷⁹ Epiduroscopy is performed with the patient in the prone position on a translucent table. Intravenous access, electrocardiographic, blood pressure, and oxygen saturation monitoring must be established. The patient is lightly sedated, making sure that communication is possible throughout the procedure.

The sacral cornua are identified. When this proves to be difficult, internal rotation of the feet will widen the gluteal cleft, thus facilitating the identification of the sacral hiatus. After anesthesia of the skin and underlying tissues, an 18-G Tuohy needle is advanced 2 to 3 cm into the sacral canal. Care must be taken not to exceed the level of S3 to prevent intradural placement of the needle and subsequent equipment. Through the Tuohy needle a guide-wire is directed cranially, as close as possible to the target area. The Manchikanti group recommends not to position the guidewire beyond the S3 level. In this case, however, there is an increased risk of dislocation when placing the introducer and performing dilation. A small incision is made at the introduction site and after removal of the Tuohy needle, a dilator is passed over the guide wire followed by the introducer sheath. The side arm of the introducer sheath is left open to allow drainage of excess saline. A flexible 0.9 mm (outer diameter) fiberoptic endoscope (magnification ×45) is introduced through one of two main access ports of a disposable 2.2 mm (outer diameter) steering catheter. The steering catheter also contains 2 side channels for fluid instillation. One side channel of the steering catheter is used for the intermittent flush of normal saline. The other side channel is connected to an automatic monitoring system by means of a standard arterial pressure monitoring system, to allow for continuous monitoring of epidural/saline delivery pressure. After distention of the sacral epidural space with normal saline, the steering catheter with the fiberoptic endoscope is slowly advanced to the target area. The epidural space is kept distended with normal saline, but the pres-

sure should be limited to minimize the risks of compromised perfusion. Total saline volume ranges between 50 and 250 mL. When fibrosis or adhesions become visible during epiduroscopy, these can be mobilized with the tip of the endoscope. It is recommended to limit the duration of the procedure to maximum 60 minutes

IV. SUMMARY

There is no gold standard for the diagnosis of lumbosacral radicular pain.

- History and clinical examination are the cornerstones of the diagnostic process.
- In case red flags are present or if an interventional treatment is being considered, medical imaging is recommended with a slight preference for MRI.
- When conservative treatment fails:
 - in (sub)acute lumbosacral radicular pain under the L3 level as a result of a contained herniation, transforaminal corticosteroid administration is recommended.
 - In chronic lumbosacral radicular pain, PRF treatment at the level of the spinal ganglion can be considered.
 - For refractory lumbosacral radicular pain, adhesiolysis and epiduroscopy can be considered, preferentially study-related.
 - In patients with a therapy-resistant radicular pain in the context of an FBSS, spinal cord stimulation is recommended in a study design.

ACKNOWLEDGEMENTS

This review was initially based on practice guidelines, written by Dutch and Flemish (Belgian) experts that are assembled in a handbook for the Dutch-speaking pain physicians. After translation, the manuscript was updated and edited in cooperation with U.S./International pain specialists. The authors thank Nicole Van den Hecke for coordination and suggestions regarding the manuscript.

CONFLICT OF INTEREST

None of the authors have conflict of interest.

REFERENCES

1. Guyatt G, Gutterman D, Baumann MH, et al. Grading strength of recommendations and quality of evidence in clinical guidelines: report from an american college of chest physicians task force. *Chest*. 2006;129:174–181.
2. van Kleef M, Mekhail N, van Zundert J. Evidence-based guidelines for interventional pain medicine according to clinical diagnoses. *Pain Pract*. 2009;9:247–251.
3. Dionne CE, Dunn KM, Croft PR, et al. A consensus approach toward the standardization of back pain definitions for use in prevalence studies. *Spine*. 2008;33:95–103.
4. Konstantinou K, Dunn KM. Sciatica: review of epidemiological studies and prevalence estimates. *Spine (Phila Pa 1976)*. 2008;33:2464–2472.
5. Khoromi S, Patsalides A, Parada S, et al. Topiramate in chronic lumbar radicular pain. *J Pain*. 2005;6:829–836.
6. Dworkin RH, O'Connor AB, Backonja M, et al. Pharmacologic management of neuropathic pain: evidence-based recommendations. *Pain*. 2007;132:237–251.
7. Younes M, Bejia I, Aguir Z, et al. Prevalence and risk factors of disk-related sciatica in an urban population in Tunisia. *Joint Bone Spine*. 2006;73:538–542.
8. Weber H. The natural course of disc herniation. *Acta Orthop Scand Suppl*. 1993;251:19–20.
9. Peul WC, Brand R, Thomeer RT, Koes BW. Influence of gender and other prognostic factors on outcome of sciatica. *Pain*. 2008;138:180–191.
10. Tarulli AW, Raynor EM. Lumbosacral radiculopathy. *Neurol Clin*. 2007;25:387–405.
11. Murphy DR, Hurwitz EL, Gerrard JK, Clary R. Pain patterns and descriptions in patients with radicular pain: does the pain necessarily follow a specific dermatome? *Chiropr Osteopat*. 2009;17:9.
12. Vroomen PC, de Krom MC, Knottnerus JA. Diagnostic value of history and physical examination in patients suspected of sciatica due to disc herniation: a systematic review. *J Neurol*. 1999;246:899–906.
13. Deville WL, van der Windt DA, Dzaferagic A, Bezemer PD, Bouter LM. The test of Lasegue: systematic review of the accuracy in diagnosing herniated discs. *Spine*. 2000;25:1140–1147.
14. Koes BW, van Tulder MW, Peul WC. Diagnosis and treatment of sciatica. *BMJ*. 2007;334:1313–1317.
15. Hofstee DJ, Gijtenbeek JM, Hoogland PH, et al. Westeinde sciatica trial: randomized controlled study of bed rest and physiotherapy for acute sciatica. *J Neurosurg*. 2002;96:45–49.
16. Jensen MC, Brant-Zawadzki MN, Obuchowski N, et al. Magnetic resonance imaging of the lumbar spine in people without back pain. *N Engl J Med*. 1994;331:69–73.
17. Delauche-Cavallier MC, Budet C, Laredo JD, et al. Lumbar disc herniation. Computed tomography scan changes after conservative treatment of nerve root compression. *Spine*. 1992;17:927–933.
18. Wiesel SW, Tsourmas N, Feffer HL, Citrin CM, Patronas N. A study of computer-assisted tomography. I. The incidence of positive CAT scans in an asymptomatic group of patients. *Spine*. 1984;9:549–551.
19. Maigne JY, Rime B, Deligne B. Computed tomographic follow-up study of forty-eight cases of nonoperatively treated lumbar intervertebral disc herniation. *Spine*. 1992;17:1071–1074.
20. Modic MT, Obuchowski NA, Ross JS, et al. Acute low back pain and radiculopathy: MR imaging findings and their prognostic role and effect on outcome. *Radiology*. 2005;237:597–604.
21. Modic MT, Ross JS, Obuchowski NA, et al. Contrast-enhanced MR imaging in acute lumbar radiculopathy: a pilot study of the natural history. *Radiology*. 1995;195:429–435.
22. Tullberg T, Svanborg E, Isaccsson J, Grane P. A preoperative and postoperative study of the accuracy and value of electrodiagnosis in patients with lumbosacral disc herniation. *Spine*. 1993;18:837–842.
23. Wolff AP, Groen GJ, Wilder-Smith OH. Influence of needle position on lumbar segmental nerve root block selectivity. *Reg Anesth Pain Med*. 2006;31:523–530.
24. Xavier AV, Farrell CE, McDanal J, Kissin I. Does antidromic activation of nociceptors play a role in sciatic radicular pain? *Pain*. 1990;40:77–79.
25. North RB, Kidd DH, Zahurak M, Piantadosi S. Specificity of diagnostic nerve blocks: a prospective, randomized study of sciatica due to lumbosacral spine disease. *Pain*. 1996;65:77–85.
26. Furman MB, Lee TS, Mehta A, Simon JI, Cano WG. Contrast flow selectivity during transforaminal lumbosacral epidural steroid injections. *Pain Physician*. 2008;11:855–861.
27. Wolff AP, Groen GJ, Crul BJ. Diagnostic lumbosacral segmental nerve blocks with local anesthetics: a prospective double-blind study on the variability and interpretation of segmental effects. *Reg Anesth Pain Med*. 2001;26:147–155.
28. Wolff AP, Wilder Smith OH, Crul BJ, van de Heijden MP, Groen GJ. Lumbar segmental nerve blocks with local anesthetics, pain relief, and motor function: a prospective double-blind study between lidocaine and ropivacaine. *Anesth Analg*. 2004;99:496–501, table of contents.
29. Le Bars D. The whole body receptive field of dorsal horn multireceptive neurones. *Brain Res Brain Res Rev*. 2002;40:29–44.
30. Wolff A, Wilder-Smith O. Diagnosis in patients with chronic radiating low back pain without overt neurological deficits: what is the value of segmental nerve root blocks? *Therapy*. 2005;2:577–585.
31. Luijsterburg PA, Lamers LM, Verhagen AP, et al. Cost-effectiveness of physical therapy and general practitioner care for sciatica. *Spine*. 2007;32:1942–1948.

32. Hagen KB, Jamtvedt G, Hilde G, Winnem MF. The updated cochrane review of bed rest for low back pain and sciatica. *Spine*. 2005;30:542–546.
33. Amlie E, Weber H, Holme I. Treatment of acute low-back pain with piroxicam: results of a double-blind placebo-controlled trial. *Spine (Phila Pa 1976)*. 1987;12:473–476.
34. Dreiser RL, Le Parc JM, Velicitat P, Llleu PL. Oral meloxicam is effective in acute sciatica: two randomised, double-blind trials versus placebo or diclofenac. *Inflamm Res*. 2001;50(suppl 1):S17–S23.
35. Luijsterburg PA, Verhagen AP, Ostelo RW, et al. Physical therapy plus general practitioners' care versus general practitioners' care alone for sciatica: a randomised clinical trial with a 12-month follow-up. *Eur Spine J*. 2008;17:509–517.
36. Atlas SJ, Keller RB, Wu YA, Deyo RA, Singer DE. Long-term outcomes of surgical and nonsurgical management of lumbar spinal stenosis: 8–10 year results from the maine lumbar spine study. *Spine*. 2005;30:936–943.
37. Weinstein JN, Tosteson TD, Lurie JD, et al. Surgical vs nonoperative treatment for lumbar disk herniation: the Spine Patient Outcomes Research Trial (SPORT): a randomized trial. *JAMA*. 2006;296:2441–2450.
38. Peul WC, van Houwelingen HC, van den Hout WB, et al. Surgery versus prolonged conservative treatment for sciatica. *N Engl J Med*. 2007;356:2245–2256.
39. Gibson JN, Waddell G. Surgical interventions for lumbar disc prolapse: updated Cochrane Review. *Spine*. 2007;32:1735–1747.
40. Jonsson B, Stromqvist B. Clinical characteristics of recurrent sciatica after lumbar discectomy. *Spine*. 1996;21:500–505.
41. Postacchini F, Giannicola G, Cinotti G. Recovery of motor deficits after microdiscectomy for lumbar disc herniation. *J Bone Joint Surg Br*. 2002;84:1040–1045.
42. CBO. Het Lumbosacrale radiculare syndroom. In: Toetsing CbvdI, ed. *Consensus Richtlijnen*. Utrecht: CBO; 1996.
43. Guigui P, Cardinne L, Rillardon L, et al. Per- and postoperative complications of surgical treatment of lumbar spinal stenosis. Prospective study of 306 patients. *Rev Chir Orthop Reparatrice Appar Mot*. 2002;88:669–677.
44. Jonsson B, Stromqvist B. Motor affliction of the L5 nerve root in lumbar nerve root compression syndromes. *Spine*. 1995;20:2012–2015.
45. Hahne AJ, Ford JJ. Functional restoration for a chronic lumbar disk extrusion with associated radiculopathy. *Phys Ther*. 2006;86:1668–1680.
46. Finnerup NB, Otto M, McQuay HJ, Jensen TS, Sindrup SH. Algorithm for neuropathic pain treatment: an evidence based proposal. *Pain*. 2005;118:289–305.
47. Saarto T, Wiffen PJ. Antidepressants for neuropathic pain. *Cochrane Database Syst Rev*. 2007;4:CD005454.
48. Yildirim K, Kataray S. The effectiveness of gabapentin in patients with chronic radiculopathy. *Pain Clin*. 2003;15:213–218.
49. DelleMijn PL, van Duijn H, Vanneste JA. Prolonged treatment with transdermal fentanyl in neuropathic pain. *J Pain Symptom Manage*. 1998;16:220–229.
50. Ng L, Chaudhary N, Sell P. The efficacy of corticosteroids in periradicular infiltration for chronic radicular pain: a randomized, double-blind, controlled trial. *Spine*. 2005;30:857–862.
51. McQuay HJ, Moore RA. *Epidural Corticosteroids for Sciatica*. Oxford, New York, Tokyo: Oxford University Press; 1998.
52. Koes BW, Scholten RJPM, Mens JMA, Bouter LM. Epidural steroid injections for low back pain and sciatica: an updated systematic review of randomized clinical trials. *Pain Digest*. 1999;9:241–247.
53. Chou R, Atlas SJ, Stanos SP, Rosenquist RW. Non-surgical interventional therapies for low back pain: a review of the evidence for an American Pain Society clinical practice guideline. *Spine (Phila Pa 1976)*. 2009;34:1078–1093.
54. Arden NK, Price C, Reading I, et al. A multicentre randomized controlled trial of epidural corticosteroid injections for sciatica: the WEST study. *Rheumatology (Oxford)*. 2005;44:1399–1406.
55. Dilke TF, Burry HC, Grahame R. Extradural corticosteroid injection in management of lumbar nerve root compression. *Br Med J*. 1973;2:635–637.
56. Wilson-MacDonald J, Burt G, Griffin D, Glynn C. Epidural steroid injection for nerve root compression. A randomised, controlled trial. *J Bone Joint Surg Br*. 2005;87:352–355.
57. Carette S, Leclaire R, Marcoux S, et al. Epidural corticosteroid injections for sciatica due to herniated nucleus pulposus. *N Engl J Med*. 1997;336:1634–1640.
58. Bogduk N. Epidural steroids. *Spine*. 1995;20:845–848.
59. Riew KD, Yin Y, Gilula L, et al. The effect of nerve-root injections on the need for operative treatment of lumbar radicular pain. A prospective, randomized, controlled, double-blind study. *J Bone Joint Surg Am*. 2000;82-A:1589–1593.
60. Karppinen J, Malmivaara A, Kurunlahti M, et al. Periradicular infiltration for sciatica: a randomized controlled trial. *Spine*. 2001;26:1059–1067.
61. Riew KD, Park JB, Cho YS, et al. Nerve root blocks in the treatment of lumbar radicular pain. A minimum five-year follow-up. *J Bone Joint Surg Am*. 2006;88:1722–1725.
62. Vad VB, Bhat AL, Lutz GE, Cammisa F. Transforaminal epidural steroid injections in lumbosacral radiculopathy: a prospective randomized study. *Spine*. 2002;27:11–16.

63. Karppinen J, Ohinmaa A, Malmivaara A, et al. Cost effectiveness of periradicular infiltration for sciatica: subgroup analysis of a randomized controlled trial. *Spine*. 2001;26:2587–2595.
64. Ackerman WE, 3rd, Ahmad M. The efficacy of lumbar epidural steroid injections in patients with lumbar disc herniations. *Anesth Analg*. 2007;104:1217–1222, tables of contents.
65. Thomas E, Cyteval C, Abiad L, et al. Efficacy of transforaminal versus interspinous corticosteroid injection in discal radiculalgia—a prospective, randomised, double-blind study. *Clin Rheumatol*. 2003;22:299–304.
66. Geurts JW, van Wijk RM, Wynne HJ, et al. Radiofrequency lesioning of dorsal root ganglia for chronic lumbosacral radicular pain: a randomised, double-blind, controlled trial. *Lancet*. 2003;361:21–26.
67. Teixeira A, Grandinson M, Sluijter M. Pulsed radiofrequency for radicular pain due to a herniated intervertebral disc—an initial report. *Pain Pract*. 2005;5:111–115.
68. Abejon D, Garcia-del-Valle S, Fuentes ML, et al. Pulsed radiofrequency in lumbar radicular pain: clinical effects in various etiological groups. *Pain Pract*. 2007;7:21–26.
69. Simopoulos TT, Kraemer J, Nagda JV, Aner M, Bajwa ZH. Response to pulsed and continuous radiofrequency lesioning of the dorsal root ganglion and segmental nerves in patients with chronic lumbar radicular pain. *Pain Physician*. 2008;11:137–144.
70. Heavner JE, Racz GB, Raj P. Percutaneous epidural neuroplasty: prospective evaluation of 0.9% NaCl versus 10% NaCl with or without hyaluronidase. *Reg Anesth Pain Med*. 1999;24:202–207.
71. Manchikanti L, Rivera JJ, Pampati V, et al. One day lumbar epidural adhesiolysis and hypertonic saline neurolysis in treatment of chronic low back pain: a randomized, double-blind trial. *Pain Physician*. 2004;7:177–186.
72. Veihelmann A, Devens C, Trouillier H, et al. Epidural neuroplasty versus physiotherapy to relieve pain in patients with sciatica: a prospective randomized blinded clinical trial. *J Orthop Sci*. 2006;11:365–369.
73. Manchikanti L, Pakanati R, Bakhit CE, Pampati V. Role of adhesiolysis and hypertonic saline neurolysis in management of low back pain. Evaluation of modification of Racz protocol. *Pain Digest*. 1999;9:91–96.
74. Gillespie G, MacKenzie P. Epiduroscopy—a review. *Scott Med J*. 2004;49:79–81.
75. Boswell MV, Trescot AM, Datta S, et al. Interventional techniques: evidence-based practice guidelines in the management of chronic spinal pain. *Pain Physician*. 2007;10:7–111.
76. Manchikanti L, Boswell MV, Rivera JJ, et al. [ISRCTN 16558617] A randomized, controlled trial of spinal endoscopic adhesiolysis in chronic refractory low back and lower extremity pain. *BMC Anesthesiol*. 2005;5:10.
77. Dashfield AK, Taylor MB, Cleaver JS, Farrow D. Comparison of caudal steroid epidural with targeted steroid placement during spinal endoscopy for chronic sciatica: a prospective, randomized, double-blind trial. *Br J Anaesth*. 2005;94:514–519.
78. Manchikanti L, Pampati V, Bakhit CE, Pakanati RR. Non-endoscopic and endoscopic adhesiolysis in post-lumbar laminectomy syndrome: a one-year outcome study and cost effectiveness analysis. *Pain Physician*. 1999;2:52–58.
79. Geurts JW, Kallewaard JW, Richardson J, Groen GJ. Targeted methylprednisolone acetate/hyaluronidase/clonidine injection after diagnostic epiduroscopy for chronic sciatica: a prospective, 1-year follow-up study. *Reg Anesth Pain Med*. 2002;27:343–352.
80. Ruetten S, Meyer O, Godolias G. Endoscopic surgery of the lumbar epidural space (epiduroscopy): results of therapeutic intervention in 93 patients. *Minim Invasive Neurosurg*. 2003;46:1–4.
81. Igarashi T, Hirabayashi Y, Seo N, et al. Lysis of adhesions and epidural injection of steroid/local anaesthetic during epiduroscopy potentially alleviate low back and leg pain in elderly patients with lumbar spinal stenosis. *Br J Anaesth*. 2004;93:181–187.
82. Raffaelli W, Righetti D. Surgical radio-frequency epiduroscopy technique (R-ResAblator) and FBSS treatment: preliminary evaluations. *Acta Neurochir Suppl*. 2005;92:121–125.
83. Sakai T, Aoki H, Hojo M, et al. Adhesiolysis and targeted steroid/local anesthetic injection during epiduroscopy alleviates pain and reduces sensory nerve dysfunction in patients with chronic sciatica. *J Anesth*. 2008;22:242–247.
84. Taylor RS, Van Buyten JP, Buchser E. Spinal cord stimulation for chronic back and leg pain and failed back surgery syndrome: a systematic review and analysis of prognostic factors. *Spine*. 2005;30:152–160.
85. Kumar K, Taylor RS, Jacques L, et al. Spinal cord stimulation versus conventional medical management for neuropathic pain: a multicentre randomised controlled trial in patients with failed back surgery syndrome. *Pain*. 2007;132:179–188.
86. Watts RW, Silagy CA. A Meta-Analysis on the efficacy of epidural corticosteroids in the treatment of sciatica. *Anaesth Intensive Care*. 1995;23:564–569.
87. Armon C, Argoff CE, Samuels J, Backonja MM. Assessment: use of epidural steroid injections to treat radicular lumbosacral pain: report of the Therapeutics and Technology Assessment Subcommittee of the American Academy of Neurology. *Neurology*. 2007;68:723–729.
88. Van Zundert J, le Polain de Waroux B. Safety of epidural steroids in daily practice: evaluation of more than 4,000 administrations. In: Monitor TI, ed. *XX Annual ESRA Meeting*. Rome: ESRA; 2000:122.

89. Abram SE, O'Connor TC. Complications associated with epidural steroid injections. *Reg Anesth*. 1996;21:149–162.
90. Houten JK, Errico TJ. Paraplegia after lumbosacral nerve root block: report of three cases. *Spine J*. 2002;2:70–75.
91. Huntoon MA, Martin DP. Paralysis after transforaminal epidural injection and previous spinal surgery. *Reg Anesth Pain Med*. 2004;29:494–495.
92. Glaser SE, Falco F. Paraplegia following a thoracolumbar transforaminal epidural steroid injection. *Pain Physician*. 2005;8:309–314.
93. Somayaji HS, Saifuddin A, Casey AT, Briggs TW. Spinal cord infarction following therapeutic computed tomography-guided left L2 nerve root injection. *Spine (Phila Pa 1976)*. 2005;30:E106–E108.
94. Quintero N, Laffont I, Bouhmidi L, et al. Transforaminal epidural steroid injection and paraplegia: case report and bibliographic review. *Ann Readapt Med Phys*. 2006;49:242–247.
95. Kennedy DJ, Dreyfuss P, Aprill CN, Bogduk N. Paraplegia following image-guided transforaminal lumbar spine epidural steroid injection: two case reports. *Pain Med*. 2009;10:1389–1394.
96. Lyders EM, Morris PP. A case of spinal cord infarction following lumbar transforaminal epidural steroid injection: MR imaging and angiographic findings. *AJNR Am J Neuroradiol*. 2009;30:1691–1693.
97. Rathmell JP, Benzon HT. Transforaminal injection of steroids: should we continue? *Reg Anesth Pain Med*. 2004;29:397–399.
98. Goodman BS, Bayazitoglu M, Mallempati S, Noble BR, Geffen JF. Dural puncture and subdural injection: a complication of lumbar transforaminal epidural injections. *Pain Physician*. 2007;10:697–705.
99. Finn KP, Case JL. Disk entry: a complication of transforaminal epidural injection—a case report. *Arch Phys Med Rehabil*. 2005;86:1489–1491.
100. Bilir A, Gulec S. Cauda equina syndrome after epidural steroid injection: a case report. *J Manipulative Physiol Ther*. 2006;29:492 e1–3.
101. Young WF. Transient blindness after lumbar epidural steroid injection: a case report and literature review. *Spine*. 2002;27:E476–E477.
102. Kabbara A, Rosenberg SK, Untal C. Methicillin-resistant *Staphylococcus aureus* epidural abscess after transforaminal epidural steroid injection. *Pain Physician*. 2004;7:269–272.
103. Hooten WM, Mizerak A, Carns PE, Huntoon MA. Discitis after lumbar epidural corticosteroid injection: a case report and analysis of the case report literature. *Pain Med*. 2006;7:46–51.
104. Simopoulos TT, Kraemer JJ, Glazer P, Bajwa ZH. Vertebral osteomyelitis: a potentially catastrophic outcome after lumbar epidural steroid injection. *Pain Physician*. 2008;11:693–697.
105. Bogduk N. Lumbar transforaminal injections of corticosteroids. In: Bogduk N, ed. *International Spine Intervention Society Practice Guidelines for Spinal Diagnoses and Treatment*. San Francisco, USA: ISIS; 2004.
106. van Kleef M, Spaans F, Dingemans W, et al. Effects and side effects of a percutaneous thermal lesion of the dorsal root ganglion in patients with cervical pain syndrome. *Pain*. 1993;52:49–53.
107. Cahana A, Van Zundert J, Macrea L, van Kleef M, Sluijter M. Pulsed radiofrequency: current clinical and biological literature available. *Pain Med*. 2006;7:411–423.
108. Sluijter ME, Cosman ER, Rittman IIWB, van Kleef M. The effects of pulsed radiofrequency field applied to the dorsal root ganglion—a preliminary report. *Pain Clin*. 1998;11:109–117.
109. Munglani R. The longer term effect of pulsed radiofrequency for neuropathic pain. *Pain*. 1999;80:437–439.
110. Pevzner E, David R, Leitner Y, et al. Pulsed radiofrequency treatment of severe radicular pain. *Harefuah*. 2005;144:178–180, 231.
111. Ramanavarapu V, Simopoulos TT. Pulsed radiofrequency of lumbar dorsal root Ganglia for chronic post-amputation stump pain. *Pain Physician*. 2008;11:561–566.
112. Chao SC, Lee HT, Kao TH, et al. Percutaneous pulsed radiofrequency in the treatment of cervical and lumbar radicular pain. *Surg Neurol*. 2008;70:59–65.
113. Talu G, Erdine S. Complications of epidural neuroplasty: a retrospective evaluation. *Neuromodulation*. 2003;6:237–347.
114. Perkins WJ, Davis DH, Huntoon MA, Horlocker TT. A retained Racz catheter fragment after epidural neurolysis: implications during magnetic resonance imaging. *Anesth Analg*. 2003;96:1717–1719, table of contents.
115. Wagner KJ, Sprenger T, Pecho C, et al. Risks and complications of epidural neurolysis—a review with case report. *Anesthesiol Intensivmed Notfallmed Schmerzther*. 2006;41:213–222.
116. Richter H. Is the so-called epidural neuroplasty (Racz catheter) a harmless procedure? In: Neurochirurgie DGf, ed. *Deutsche Gesellschaft Fur Neurochirurgie*. Strasbourg, Germany: Deutsche Gesellschaft fur Neurochirurgie; 2005.
117. Kumar K, Buchser E, Linderth B, Meglio M, Van Buyten JP. Avoiding Complications from spinal cord stimulation: practical recommendations from an international panel of experts. *Neuromodulation*. 2007;10:24–33.
118. Luijsterburg PA, Verhagen AP, Ostelo RW, et al. Effectiveness of conservative treatments for the lumbosacral radicular syndrome: a systematic review. *Eur Spine J*. 2007;16:881–899.
119. Abdi S, Datta S, Trescot AM, et al. Epidural steroids in the management of chronic spinal pain: a systematic review. *Pain Physician*. 2007;10:185–212.

120. DePalma MJ, Bhargava A, Slipman CW. A critical appraisal of the evidence for selective nerve root injection in the treatment of lumbosacral radiculopathy. *Arch Phys Med Rehabil.* 2005;86:1477–1483.
121. Vroomen PC, de Krom MC, Slofstra PD, Knottnerus JA. Conservative treatment of sciatica: a systematic review. *J Spinal Disord.* 2000;13:463–469.
122. Koes B, Scholten RJ, Mens JMA, Bouter LM. Efficacy of epidural steroid injections for low-back pain and sciatica: a systematic review of randomized clinical trials. *Pain.* 1995;63:279–288.
123. Benzon HT, Chew TL, McCarthy RJ, Benzon HA, Walega DR. Comparison of the particle sizes of different steroids and the effect of dilution: a review of the relative neurotoxicities of the steroids. *Anesthesiology.* 2007;106:331–338.
124. O'Donnell C, Cano W, D'Eramo G. Comparison of triamcinolone to dexamethasone in the treatment of low back and leg pain via lumbar transforaminal epidural steroid injection. In: ISIS, ed. *North American Spine Society 23rd Annual Meeting.* Toronto: ISIS; 2008.
125. Owlia MB, Salimzadeh A, Alishiri G, Haghighi A. Comparison of two doses of corticosteroid in epidural steroid injection for lumbar radicular pain. *Singapore Med J.* 2007;48:241–245.
126. Novak S, Nemeth WC. The basis for recommending repeating epidural steroid injections for radicular low back pain: a literature review. *Arch Phys Med Rehabil.* 2008;89:543–552.
127. Waldman SD. *Waldman Interventional Pain Management.* Philadelphia, PA: W.B. Saunders; 2001.
128. Merrill DG, Rathmell JP, Rowlingson JC. Epidural steroid injections. *Anesth Analg.* 2003;96:907–908, author reply 8.
129. Cluff R, Mehio AK, Cohen SP, et al. The technical aspects of epidural steroid injections: a national survey. *Anesth Analg.* 2002;95:403–408, table of contents.
130. Botwin K, Gruber R, Bouchlas C, et al. Complications of fluoroscopically guided transforaminal lumbar epidural injections. *Arch Phys Med Rehabil.* 2000;81:1045–1050.
131. Lou L, Racz G. Spinal decompressive neuroplasty via the caudal and cervical approaches. In: Beltrutti D, Benzon HT, Erdine S, et al., eds. *Raj: Textbook of Regional Anesthesia.* 1st ed. Philadelphia, Pennsylvania, US: Churchill Livingstone; 2002.
132. Heavner J, Chokhavatia S, Kizelshteyn G. Percutaneous evaluation of the epidural and subarachnoid space with a flexible fiberscope. *Reg Anesth.* 1991;15:85.
133. Manchikanti L, Pampati V. Role of one day epidural adhesiolysis in management of chronic low back pain: a randomized clinical trial. *Pain Physician.* 2001;4:153–166.