
EVIDENCE-BASED MEDICINE

Evidence-based Interventional Pain Medicine
according to Clinical Diagnoses

12. Pain Originating from the Lumbar Facet Joints

Maarten van Kleef, MD, PhD, FIPP*; Pascal Vanelderren, MD, FIPP^{†,‡};
Steven P. Cohen, MD^{§,¶}; Arno Lataster, MSc^{**};
Jan Van Zundert, MD, PhD, FIPP^{*,‡}; Nagy Mekhail, MD, PhD, FIPP^{††}

**Department of Anesthesiology and Pain Management, University Medical Centre Maastricht, Maastricht, The Netherlands; †Department of Anesthesiology, Intensive Care Medicine, Multidisciplinary Pain Centre, Ziekenhuis Oost-Limburg, Genk, Belgium;*

‡Department of Pain Management and Palliative Care Medicine, Radboud University Nijmegen Medical Centre, Nijmegen, The Netherlands; §Department of Anesthesiology & Critical Care Medicine, John Hopkins School of Medicine, Baltimore, Maryland;

*¶Walter Reed Army Medical Center, Washington, District of Columbia, USA; **Department of Anatomy and Embryology, Maastricht University, Maastricht, The Netherlands;*

††Department of Pain Management, Cleveland Clinic, Cleveland, Ohio, USA

■ **Abstract:** Although the existence of a “facet syndrome” had long been questioned, it is now generally accepted as a clinical entity. Depending on the diagnostic criteria, the zygapophysial joints account for between 5% and 15% of cases of chronic, axial low back pain. Most commonly, facetogenic pain is the result of repetitive stress and/or cumulative low-level trauma, leading to inflammation and stretching of the joint capsule. The most frequent complaint is axial low back pain with referred pain perceived in the flank, hip, and thigh. No physical examination findings are pathognomonic for diagnosis. The strongest indicator for lumbar facet pain is pain reduction after anesthetic blocks of the rami mediales

(medial branches) of the rami dorsales that innervate the facet joints. Because false-positive and, possibly, false-negative results may occur, results must be interpreted carefully. In patients with injection-confirmed zygapophysial joint pain, procedural interventions can be undertaken in the context of a multidisciplinary, multimodal treatment regimen that includes pharmacotherapy, physical therapy and regular exercise, and, if indicated, psychotherapy. Currently, the “gold standard” for treating facetogenic pain is radiofrequency treatment (1 B+). The evidence supporting intra-articular corticosteroids is limited; hence, this should be reserved for those individuals who do not respond to radiofrequency treatment (2 B±). ■

Address correspondence and reprint requests to: Maarten van Kleef, MD, PhD, FIPP, Maastricht University Medical Centre, Department of Anesthesiology and Pain Management, PO Box 5800, 6202 AZ Maastricht, The Netherlands. E-mail: maarten.van.kleef@mumc.nl.

DOI: 10.1111/j.1533-2500.2010.00393.x

Key Words: evidence-based medicine, low back pain, zygapophysial joint, lumbar facet, radiofrequency treatment

INTRODUCTION

This review on facetogenic low back pain is part of the series “Evidence-Based Interventional Pain Medicine

Table 1. Summary of Evidence Scores and Implications for Recommendation

Score	Description	Implication
1 A+	Effectiveness demonstrated in various RCTs of good quality. The benefits clearly outweigh risk and burdens	} Positive recommendation
1 B+	One RCT or more RCTs with methodologic weaknesses, demonstrate effectiveness. The benefits clearly outweigh risk and burdens	
2 B+	One or more RCTs with methodologic weaknesses, demonstrate effectiveness. Benefits closely balanced with risk and burdens	
2 B±	Multiple RCTs, with methodologic weaknesses, yield contradictory results better or worse than the control treatment. Benefits closely balanced with risk and burdens, or uncertainty in the estimates of benefits, risk and burdens.	} Considered, preferably study-related
2 C+	Effectiveness only demonstrated in observational studies. Given that there is no conclusive evidence of the effect, benefits closely balanced with risk and burdens	
0	There is no literature or there are case reports available, but these are insufficient to suggest effectiveness and/or safety. These treatments should only be applied in relation to studies.	Only study-related
2 C-	Observational studies indicate no or too short-lived effectiveness. Given that there is no positive clinical effect, risk and burdens outweigh the benefit	} Negative recommendation
2 B-	One or more RCTs with methodologic weaknesses, or large observational studies that do not indicate any superiority to the control treatment. Given that there is no positive clinical effect, risk and burdens outweigh the benefit	
2 A-	RCT of a good quality which does not exhibit any clinical effect. Given that there is no positive clinical effect, risk and burdens outweigh the benefit	

RCT, randomized controlled trial.

according to Clinical Diagnoses.” Recommendations formulated in this article are based on “Grading strength of recommendations and quality of evidence in clinical guidelines” described by Guyatt et al.¹ and adapted by van Kleef et al.² in the editorial accompanying the first article of this series (Table 1). The latest literature update was performed in October 2009.

Pain emanating from the lumbar facet joints is a common cause of low back pain in the adult population. Golthwaite was the first to describe the syndrome in 1911, and Ghormley is generally credited with coining the term “facet syndrome” in 1933. Facet pain is defined as pain that arises from any structure that is part of the facet joints, including the fibrous capsule, synovial membrane, hyaline cartilage, and bone.³⁻⁵

The reported prevalence rate varies widely in different studies from less than 5% to as high as 90%, being heavily dependent on diagnostic criteria and selection methods.⁶⁻¹³ Based on information from studies that were done on well-selected patient populations, we estimate the prevalence to range between 5% and 15% of the population with axial low back pain.¹⁴⁻¹⁷ Because arthritis is a prominent cause of facetogenic pain, the prevalence rate increases with age.^{18,19}

Although some experts have expressed doubts about the validity of “facet syndrome,” studies conducted in patients and volunteers have confirmed its

existence.²⁰⁻²⁵ In rare cases, facet joint pain can result from a specific traumatic event (ie, high-energy trauma associated with a combination of hyperflexion, extension, and distraction).²⁶ More commonly, it is the result of repetitive stress and/or cumulative low-level trauma. This leads to inflammation, which can cause the facet joint to be filled with fluid and swell, which in turn results in stretching of the joint capsule and subsequent pain generation.²⁷ Inflammatory changes around the facet joint can also irritate the spinal nerve via foraminal narrowing, resulting in sciatica. In addition, Igarashi et al.²⁸ found that inflammatory cytokines released through the ventral joint capsule in patients with zygapophysial joint degeneration may be partially responsible for the neuropathic symptoms in individuals with spinal stenosis. Predisposing factors for zygapophysial joint pain include spondylolisthesis/lysis, degenerative disc disease, and advanced age.⁵

The treatment of facet pain is the subject of great controversy. In 1963, Hirsch et al.²¹ were the first group to describe the technique of facet joint injections, and in the mid-1970s, Shealy published the first reports of radiofrequency (RF) treatment of the zygapophysial joints under radiographic guidance.^{29,30} Because each facet joint receives dual innervation from adjacent levels and most individuals have multilevel pathology, several levels usually need to be treated³¹⁻³³ (Figure 1).

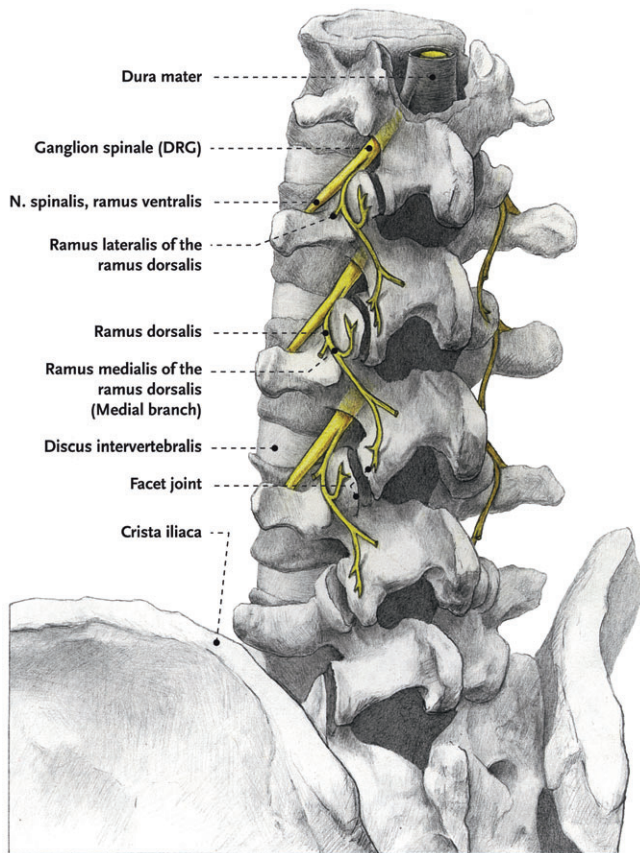


Figure 1. Anatomy of the lumbar spinal column. "Illustration: Rogier Trompert Medical Art. <http://www.medical-art.nl>." DRG, dorsal root ganglion.

I. DIAGNOSIS

I.A HISTORY

A number of researchers have attempted to elucidate the clinical entity "facetogenic pain," mostly through provocation of pain in volunteers.^{23,34–39}

The most frequent complaint is axial low back pain. Although bilateral symptoms are more common than for sacroiliac joint pain, centralization of pain is less predictive of response to analgesic blocks than it is for discogenic pain.^{40,41} Sometimes, pain may be referred into the groin or thigh.²³ Pain originating from the upper facet joints often extends into the flank, hip, and lateral thigh regions, whereas pain from the lower facet joints typically radiates into the posterior thigh. Pain distal to the knee is rarely associated with facet pathology (Figure 2).

I.B PHYSICAL EXAMINATION

There are no physical examination findings that are pathognomonic for diagnosis. Because facet pain

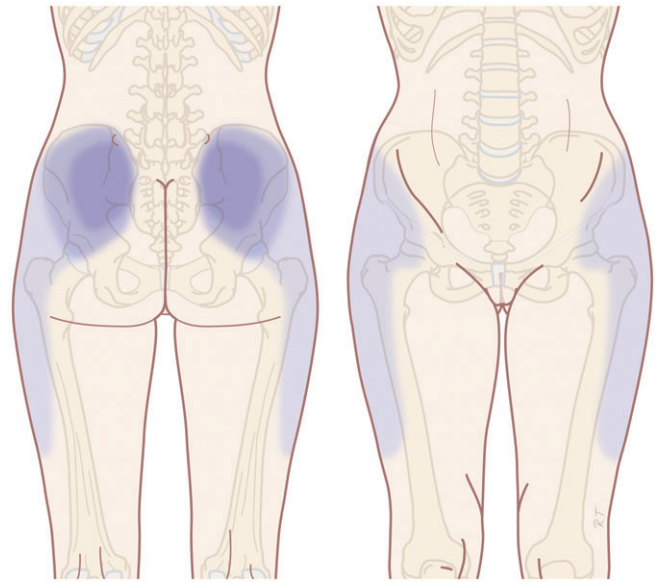


Figure 2. Pain referral pattern of lumbar facet pain adapted from McCall et al.²³ "Illustration: Rogier Trompert Medical Art. <http://www.medical-art.nl>."

originates from the mobile elements of the back, examination of motion seems relevant. In a series of cadaveric studies, Ianuzzi et al.⁴² determined that the largest strain on the lower lumbar facet joints occurred during flexion and lateral bending, with extension also stressing L5/S1. It is therefore possible that pain worsened by flexion and extension is suggestive of pathology originating from the lowest lumbar segment(s).

Revel was the first to correlate symptoms and physical exam signs with the response to placebo-controlled blocks.^{14,39}

The Revel criteria for lumbar facet joint pain are as follows:

- Pain not worsened by coughing.
- Pain not worsened by straightening from flexion.
- Pain not worsened by extension–rotation.
- Pain not worsened by hyperextension.
- Pain improved in the supine position.

However, previous and subsequent studies have failed to corroborate these findings.^{43–45} It is widely acknowledged that lumbar paravertebral tenderness is indicative of facetogenic pain, which is a claim supported by clinical trials.⁴⁶ Recently, indicators of facet pain have been described based on a survey of an expert panel. They specified a panel of 12 indicators that create the framework for a diagnosis of facet pain.⁴⁷ These indicators are not in line with previous studies.^{39,46,48}

I.C ADDITIONAL TESTS

The prevalence rate of pathological changes in the facet joints on radiological examination depends on the mean age of the subjects, the radiological technique used, and the definition of “abnormality.” Degenerative facet joints can be best visualized via computed tomography (CT) examination.⁴⁹

CT studies conducted in patients with low back pain show a prevalence rate of facet joint degeneration ranging between 40% and 80%.^{12,50} magnetic resonance imaging scans may be somewhat less sensitive in the detection of facet pathology.^{7,49} Interestingly, the number of studies demonstrating a positive correlation between radiological abnormalities and the response to diagnostic blocks is roughly equivalent to the number showing no correlation.^{7,11–14,32,36,37,43,50–52}

I.D DIFFERENTIAL DIAGNOSIS

As earlier indicated in the literature on guidelines for chronic nonspecific low back complaints, supplementary radiological examination may also be necessary to rule out so-called “red flags” such as malignancy, compression fracture, or spinal infection.^{18,53}

Other causes of predominantly axial low back pain that must be considered in the differential diagnosis include discogenic pain, sacroiliac joint pathology, ligamentous injury, and myofascial pain. Within the context of facet pathology, inflammatory arthritides, such as rheumatoid arthritis, ankylosing spondylitis, gout, psoriatic arthritis, reactive arthritis, and other spondylarthropathies, as well as osteoarthritis and synovitis, must also be considered.

Diagnostic Blocks

Diagnostic blocks are most frequently performed under radiographic guidance but can also be done under ultrasound.^{54,55} Although intra-articular injection and medial branch (facet joint nerve) blocks are often described as “equivalent,” this has yet to be demonstrated in a comparative, crossover study design.⁵ Neither of these approaches have been shown to be superior.²² Both medial branch and intra-articular blocks are associated with significant false-positive and false-negative rates. For both techniques, the rate of false positives is most often cited as ranging between 15% and 40%.⁵ Regarding the false-negative rate, Kaplan et al. found that 11% of volunteers retained the ability to perceive capsular distension after appropriately performed medial branch blocks, which was attributed to aberrant innervation.⁵⁶

Other causes of false-negative blocks include inappropriate needle placement, failure to detect vascular uptake, and inability of the patient to discern baseline from procedure-related pain.⁵⁷

False-positive results can be ascribed to several phenomena including placebo response, use of sedation, and/or the excessive use of superficial local anesthesia, which can obscure myofascial pain.^{58,59} In addition, the local anesthetic can spread to surrounding pain-generating structures. Over 70 years ago, Kellegren noted that an intramuscular injection of 0.5 mL of fluid spreads over an area encompassing 6 cm² of tissue, and this was later confirmed by Cohen and Raja.^{5,60} Dreyfuss et al.⁵⁷ found that either epidural or intervertebral foraminal spread occurred in 16% of blocks using the traditional target point at the superior junction of the processus transversus and processus articularis superior. Given the close proximity of the ramus lateralis and intermedius to the ramus medialis (medial branch) of the primary ramus dorsalis, it is not possible to selectively block one without the others. During intra-articular facet blocks, the capsule can rupture after the injection of 1 to 2 mL of injection fluid with the resultant spread of the local anesthetic to other potential pain-generating structures.

Perhaps because of their safety, simplicity, and prognostic value, diagnostic medial branch blocks are done more frequently than intra-articular injections. Dreyfuss et al.⁵⁷ researched the ideal needle position for diagnostic medial branch blocks. They compared 2 different target sites—one with the needle tip positioned on the upper edge of the processus transversus and the other with the needle tip located halfway between the upper edge of the processus transversus and the ligamentum mammilloaccessorium. The authors found that the lower (ie, latter) target position was associated with a lower incidence of inadvertent injectate spread to the segmental nerves and epidural space when a volume of 0.5 mL was used. It is thus recommended to use the lower target site when performing diagnostic medial branch blocks.

After the procedure, the patient is given a pain diary with instructions to discount procedure-related discomfort and engage in normal activities in order to permit adequate assessment of effectiveness. Failure to properly discriminate between baseline pain and that related to the procedure is a common cause of false-negative blocks.

In general, a definitive treatment is carried out if a patient experiences 50% or greater pain reduction lasting for the duration of action of the local anesthetic (eg, >30 minutes with lidocaine and 3 hours with bupivacaine). Because double, comparative blocks are

associated with a significant false-negative rate and have not been shown to be cost-effective, the “double-block” paradigm is not advisable at this time.^{61–63}

II. TREATMENT OPTIONS

II.A CONSERVATIVE MANAGEMENT

The treatment of facet pain should ideally occur in a multidisciplinary fashion and include conservative (pharmacological treatment, cognitive behavioral therapy, manual medicine, exercise therapy and rehabilitation, and, if necessary, a more detailed psychological evaluation) as well as interventional pain management techniques.

Because there are no clinical studies evaluating pharmacological or non-interventional treatments for patients with injection-confirmed facet joint pain, one must extrapolate from studies that have been conducted on patients with chronic nonspecific low back complaints. Although nonsteroidal anti-inflammatory drugs are often used, scientific evidence supporting their long-term use for low back complaints is scant.⁵³ Antidepressants appear to be effective, though the treatment effect is small.⁶⁴ Manipulation can also be effective,^{65,66} although 1 study showed no difference with “sham” therapy.⁶⁷

II.B INTERVENTIONAL MANAGEMENT

Currently, the gold standard for treating facetogenic pain is RF treatment. The major advantage of temperature-controlled RF treatment compared with voltage-controlled and other “neurolytic” techniques is that it produces controlled and reproducible lesion dimensions.⁶⁸ RF facet treatment can also be repeated without a loss of efficacy, which is important because the duration of benefit is limited by the inexorable rate of nerve regeneration.⁶⁹ There are currently no randomized studies comparing RF facet treatment with intra-articular injections.⁵

Intra-Articular Corticosteroid Injections

The use of intra-articular corticosteroid injections in the facet joints is controversial. Uncontrolled studies have mostly demonstrated transient beneficial effects, but the results of controlled studies have been mostly disappointing. Lilius et al.⁷⁰ performed the largest randomized study, involving 109 patients. They found no difference among large-volume (8 mL) intra-articular saline injections, intra-articular corticosteroid, and local anesthetic, and the same mixture injected around 2 facet

joints. In a randomized, controlled study, Carette et al.⁷¹ found only a small difference between the injection of saline (10% good effect) and depot corticosteroid (22% good effect) up to 6 months after treatment. One caveat with placebo-controlled trials that is not commonly recognized is that the intra-articular injection of saline may itself provide therapeutic benefit.⁷² Observational studies involving intra-articular local anesthetic and corticosteroid typically show symptom palliation lasting for up to 3 months.^{51,73} Based on the literature, one can conclude that intra-articular corticosteroid injections are of very limited value in the treatment of unscreened patients with suspected facetogenic pain. However, subgroup analyses have revealed that patients with positive single photon emission CT scans may be more likely to respond than patients without an acute inflammatory process.^{73,74}

RF Treatment

RF treatment is frequently performed for various forms of spinal pain, though the scientific evidence for this intervention remains controversial. The first controlled study was published by Gallagher et al. in 1994.⁷⁵ The authors selected 41 patients with chronic low back complaints who responded with some pain relief to diagnostic intra-articular injections and randomized them to receive either “sham” or true RF treatment of the rami mediales (medial branches). The 2 study groups were then subdivided into patients who obtained “good” and “equivocal” relief after the diagnostic block. After 6 months, a significant difference was found only between treatment and control subjects who had experienced good relief from the test blocks. In a well-designed placebo-controlled study, van Kleef et al.⁷⁶ demonstrated good results after RF treatment lasting up to 12 months after treatment. Leclaire et al.⁷⁷ did not establish a therapeutic effect for RF treatment in a placebo-controlled trial, but this study has been criticized because the criterion for a positive “diagnostic” block was ≥ 24 hours of pain relief after lidocaine infiltration, which is inconsistent with the drug’s pharmacokinetics. In addition, 94% of the screened patients with back pain were selected for participation, which is much greater than the presumed prevalence for lumbar facetogenic pain (17% to 30%) in this cohort. For this reason, this study is judged to have major methodological flaws. van Wijk et al.⁷⁸ also found no difference between the treatment and control groups with regard to visual analog scale pain score, medication usage, and function. However, the RF group in this study did report

≥50% reduction in complaints significantly more often (62% vs. 39%) than those who received a sham procedure. The evaluation method was, however, subject to discussion. Finally, in the most recent randomized placebo-controlled trial undertaken in 40 patients who obtained significant pain relief following 3 diagnostic blocks, a significantly greater improvement in pain symptoms, global perception of improvement, and quality of life was observed after 6 months in those subjects allocated to RF treatment.¹⁷ In 2 randomized studies comparing pulsed and conventional RF treatment for facetogenic pain, both showed conventional RF to be superior.^{79,80}

From these 7 controlled studies, one can conclude that RF treatment of the facet joints can provide intermediate-term benefit in carefully selected patients.

However, in a recent review, the value of this intervention was questioned.⁸¹ In a letter to the editor, the methodology was questioned, and a meta-analysis was performed. When including the 6 randomized controlled trials, RF was significantly better than placebo. Even when only the 2 trials without shortcomings were included, the difference in favor of RF treatment remained significant.⁸²

II.C COMPLICATIONS OF INTERVENTIONAL MANAGEMENT

Complications of Diagnostic Blocks

The most prevalent complication of a diagnostic block results from an overflow of local anesthetic to the segmental nerves. This can cause temporary paresthesias in the legs and loss of motor function.

Complications of RF Treatment

The complications and side effects of RF treatment have been previously described in a small retrospective study by Kornick et al.⁸³ Out of 116 procedures, the 2 most commonly occurring complications were transient, localized burning pain and self-limiting back pain lasting longer than 2 weeks, each occurring with a frequency of 2.5% per procedure. In this study, no infections, motor, or new sensory deficits were identified.

Unlike diagnostic blocks, which, in rare instances, have been complicated by spinal infection(s), RF treatment has never been associated with infectious complications.⁸⁴ This may be because heat lesioning serves a protective function. In rare instances, local burns and motor weakness have been reported.^{5,85}

Table 2. Evidence for the Treatment Options for Lumbar Facetogenic Pain

Technique	Assessment
Intra-articular injections	2 B±
Radiofrequency treatment of the rami mediales (medial branches) and L5 primary rami dorsales	1 B+

Other Treatment Options

There is presently no evidence to support the use of operative interventions for injection-confirmed facetogenic pain.⁵ Although several devices have been used and advocated for percutaneous facet joint fusion, none have been evaluated in rigorous trials.

II.D EVIDENCE FOR INTERVENTIONAL MANAGEMENT

A summary of the available evidence is given in Table 2.

III. RECOMMENDATIONS

In patients with chronic low back pain putatively originating from the facet joints, RF treatment of the rami mediales (medial branches) arising from rami dorsales of lumbar segmental nerves can be recommended after a positive diagnostic block.

III.A CLINICAL PRACTICE ALGORITHM

A practice algorithm for the management of lumbar facet pain is illustrated in Figure 3.

III.B TECHNIQUES

Procedure for RF Treatment of the Lumbar Facet Joints

There are several ways to perform lumbar facet RF treatment, and comparative studies between different techniques are lacking. This section describes just 1 technique. RF treatment is a procedure that requires continuous feedback from the patient during the procedure. Therefore, if sedation is used, it should be light enough to enable conversation. The patient is placed in a prone position on an examination table. A cushion is placed under the abdomen to straighten the physiological lumbar lordosis. First, the anatomical structures are identified with an anterior-posterior examination. Next, the C-arm is rotated axially to align the X-ray beam parallel with the L4–L5 disc to remove parallax of the end plates. The C-arm is then rotated approximately 15° obliquely to the ipsilateral side so that the junction between the processus articularis superior and the processus transversus, the traditional target point, is more

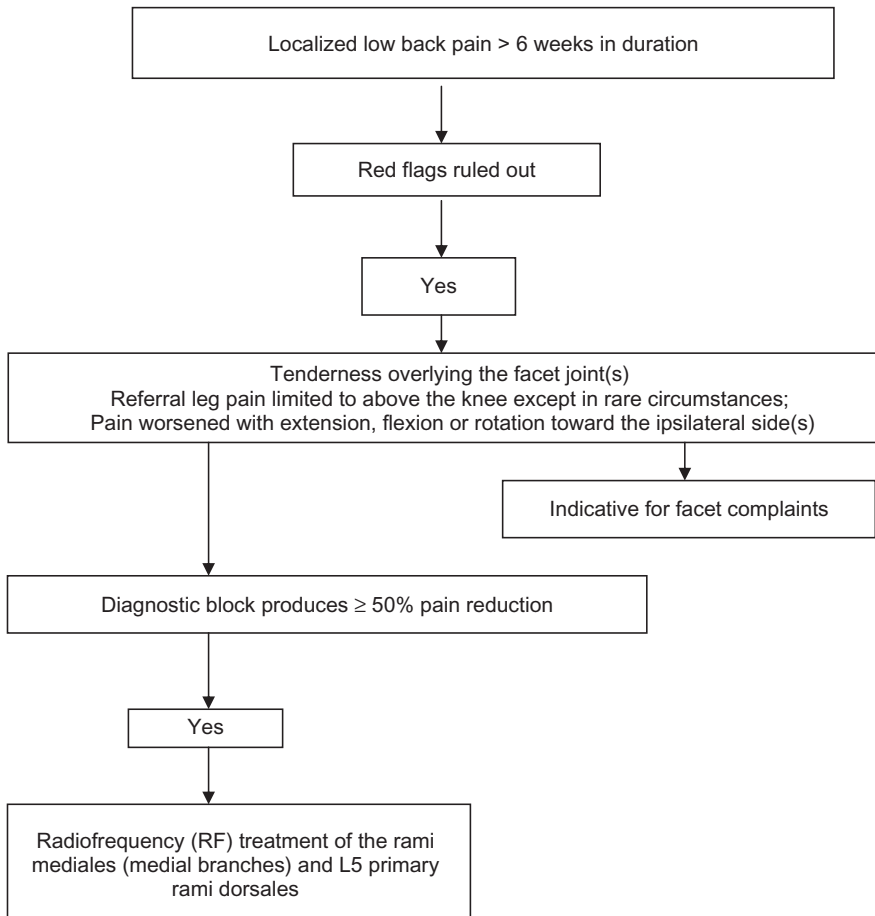


Figure 3. Practice algorithms for the treatment of lumbar facet pain.

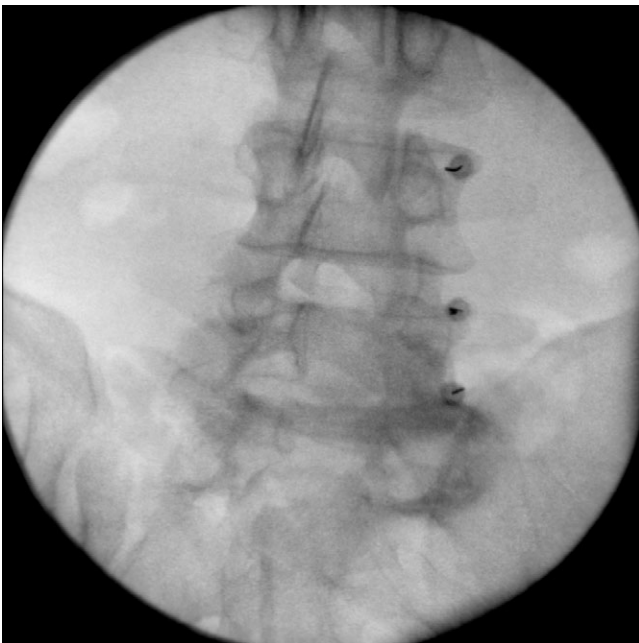


Figure 4. Radiofrequency treatment of L3, L4, and L5 dorsal rami/facet, oblique view.

easily accessible. Several preclinical studies have demonstrated that placing the active tip parallel to the course of the nerve maximizes lesion size.^{86,87} Hence, if the practitioner desires to orient the electrode parallel to the targeted nerve in a co-axial view to facilitate placement, the image intensifier can be further angled in the caudad direction.

The injection point is then marked on the skin. The traditional target is the cephalad junction between the processus articularis superior and the processus transversus. However, 1 cadaveric study and literature review determined the optimal needle position to be with the electrode tip lying across the lateral neck of the processus articularis superior.⁸⁶

When inserting the electrode, one should first make contact with the processus transversus as close as possible to the processus articularis superior. After contacting bone, the needle is advanced slightly in a cranial direction so that the tip slides over the processus transversus (Figure 4). In the lateral fluoroscopic view, the electrode tip should now lie at the base of the processus

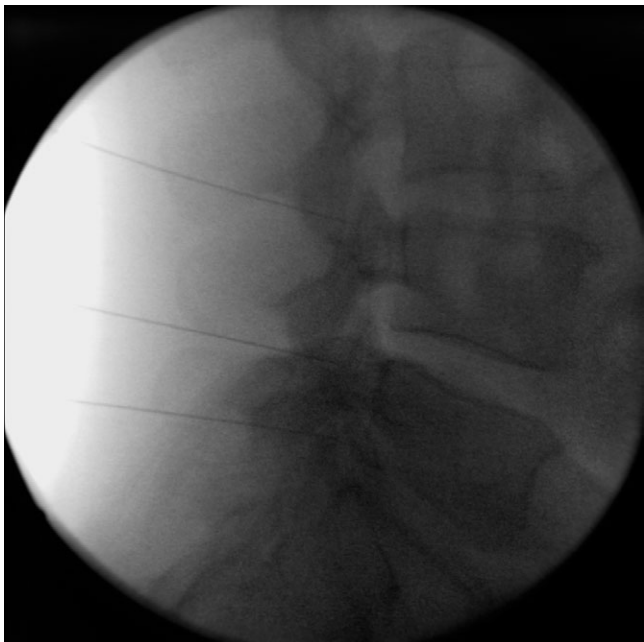


Figure 5. Radiofrequency treatment of L3, L4, and L5 dorsal rami/facet, lateral view.

articularis superior in the plane formed by the so-called facet column at the lower aspect of the foramen intervertebrale, approximately 1 mm dorsal to its posterior border (Figure 5). When proper needle position is confirmed in multiple views, the impedance is checked and a sensory stimulus current of 50 Hz is applied. The electrode position is generally deemed adequate if concordant stimulation is obtained at ≤ 0.5 V. Motor stimulation at 2 Hz serves to confirm correct needle placement via contraction of the musculus multifidus and to ensure the absence of distal muscle contraction in the leg, which indicates improper placement. Local muscle contractions in the back can generally be observed and palpated by the practitioner, though this is not always detectable. If leg movement is observed or the patient feels contractions in the leg, the needle must be repositioned. When the practitioner is confident that the needle is properly positioned, 0.5 mL of local anesthetic is injected.

After a brief interval in which the local anesthetic takes effect, a $\geq 67^\circ$ lesion is applied for at least 1 minute. The nerve location and technique are the same for the ramus medialis (medial branch) of the nerves L1–L4. For L5, it is the ramus dorsalis itself that is amenable to lesioning, as it courses along the junction between the ala and processus articularis ossis sacri. At this level, 2 Hz stimulation does not always produce prominent contraction of the musculus multifidus, yet motor stimulation

should be performed to prevent inadvertent lesioning too close in proximity to the segmental nerve.

CONCLUSIONS

Lumbar facet joint pain is a common yet controversial source of low back pain. Although the diagnosis is generally made by either medial branch or intra-articular injections, both are subject to high false-positive and, possibly, false-negative rates. To date, superiority or equivalence has yet to be established in comparative crossover studies. In patients with injection-confirmed zygapophysial joint pain, procedural interventions can be undertaken in the context of a multidisciplinary, multimodal treatment regimen that includes pharmacotherapy, physical therapy and regular exercise, and, if indicated, psychotherapy. Currently, the “gold standard” for treating facetogenic pain is RF treatment, though the effect size is moderate, and the duration is limited to less than a year. The evidence supporting intra-articular corticosteroids is largely anecdotal.

IV. SUMMARY

There is no gold standard for making the diagnosis of low back complaints originating from the facet joints.

Unilateral localized back pain without radicular referral and pain in a movement examination together with paravertebral pressure pain appear to support this diagnosis.

However, the diagnosis must be confirmed by a diagnostic block of the suspected painful facet joints. If this treatment produces a pain reduction of at least 50%, moving to a RF treatment seems justified. If RF treatment is contraindicated, a 1-time intra-articular injection with local anesthetic can be considered.

ACKNOWLEDGEMENTS

This review was initially based on practice guidelines written by Dutch and Flemish (Belgian) experts that are assembled in a handbook for the Dutch-speaking pain physicians. After translation, the article was updated and edited in cooperation with U.S./international pain specialists.

The authors thank José Geurts and Nicole Van den Hecke for coordination and suggestions regarding the article.

REFERENCES

1. Guyatt G, Gutterman D, Baumann MH, et al. Grading strength of recommendations and quality of evidence

- in clinical guidelines: report from an American College of Chest Physicians Task Force. *Chest*. 2006;129:174–181.
2. van Kleef M, Mekhail N, van Zundert J. Evidence-based guidelines for interventional pain medicine according to clinical diagnoses. *Pain Pract*. 2009;9:247–251.
 3. Goldthwaite J. The lumbosacral articulation: an explanation of many cases of lumbago, sciatica, and paraplegia. *Boston Med Surg J*. 1911;365–372.
 4. Ghormley R. Low back pain with special reference to the articular facets, with presentation of an operative procedure. *JAMA*. 1933;1773–1777.
 5. Cohen SP, Raja SN. Pathogenesis, diagnosis, and treatment of lumbar zygapophysial (facet) joint pain. *Anesthesiology*. 2007;106:591–614.
 6. Long DM, BenDebba M, Torgerson WS, et al. Persistent back pain and sciatica in the United States: patient characteristics. *J Spinal Disord*. 1996;9:40–58.
 7. Murtagh FR. Computed tomography and fluoroscopy guided anesthesia and steroid injection in facet syndrome. *Spine*. 1988;13:686–689.
 8. Destouet JM, Gilula LA, Murphy WA, Monsees B. Lumbar facet joint injection: indication, technique, clinical correlation, and preliminary results. *Radiology*. 1982;145:321–325.
 9. Lau LS, Littlejohn GO, Miller MH. Clinical evaluation of intra-articular injections for lumbar facet joint pain. *Med J Aust*. 1985;143:563–565.
 10. Moran R, O'Connell D, Walsh MG. The diagnostic value of facet joint injections. *Spine*. 1988;13:1407–1410.
 11. Raymond J, Dumas JM. Intraarticular facet block: diagnostic test or therapeutic procedure? *Radiology*. 1984;151:333–336.
 12. Carrera GF. Lumbar facet joint injection in low back pain and sciatica: description of technique. *Radiology*. 1980;137:661–664.
 13. Lewinnek GE, Warfield CA. Facet joint degeneration as a cause of low back pain. *Clin Orthop Relat Res*. 1986;213:216–222.
 14. Revel ME, Listrat VM, Chevalier XJ, et al. Facet joint block for low back pain: identifying predictors of a good response. *Arch Phys Med Rehabil*. 1992;73:824–828.
 15. Dreyfuss P, Halbrook B, Pauza K, Joshi A, McLarty J, Bogduk N. Efficacy and validity of radiofrequency neurotomy for chronic lumbar zygapophysial joint pain. *Spine*. 2000;25:1270–1277.
 16. Manchikanti L, Boswell MV, Singh V, Pampati V, Damron KS, Beyer CD. Prevalence of facet joint pain in chronic spinal pain of cervical, thoracic, and lumbar regions. *BMC Musculoskelet Disord*. 2004;5:15.
 17. Nath S, Nath CA, Pettersson K. Percutaneous lumbar zygapophysial (facet) joint neurotomy using radiofrequency current, in the management of chronic low back pain: a randomized double-blind trial. *Spine*. 2008;33:1291–1297, discussion 8.
 18. Hicks GE, Morone N, Weiner DK. Degenerative lumbar disc and facet disease in older adults: prevalence and clinical correlates. *Spine (Phila Pa 1976)*. 2009;34:1301–1306.
 19. Manchikanti L, Manchikanti KN, Cash KA, Singh V, Giordano J. Age-related prevalence of facet-joint involvement in chronic neck and low back pain. *Pain Physician*. 2008;11:67–75.
 20. Cavanaugh JM, Ozaktay AC, Yamashita HT, King AI. Lumbar facet pain: biomechanics, neuroanatomy and neurophysiology. *J Biomech*. 1996;29:1117–1129.
 21. Hirsch C, Ingelmark BE, Miller M. The anatomical basis for low back pain. Studies on the presence of sensory nerve endings in ligamentous, capsular and intervertebral disc structures in the human lumbar spine. *Acta Orthop Scand*. 1963;33:1–17.
 22. Marks RC, Houston T, Thulbourne T. Facet joint injection and facet nerve block: a randomised comparison in 86 patients with chronic low back pain. *Pain*. 1992;49:325–328.
 23. McCall IW, Park WM, O'Brien JP. Induced pain referral from posterior lumbar elements in normal subjects. *Spine*. 1979;4:441–446.
 24. Kuslich SD, Ulstrom CL, Michael CJ. The tissue origin of low back pain and sciatica: a report of pain response to tissue stimulation during operations on the lumbar spine using local anesthesia. *Orthop Clin North Am*. 1991;22:181–187.
 25. Mooney V, Robertson J. The facet syndrome. *Clin Orthop Relat Res*. 1976;115:149–156.
 26. Song KJ, Lee KB. Bilateral facet dislocation on L4-L5 without neurologic deficit. *J Spinal Disord Tech*. 2005;18:462–464.
 27. Yang KH, King AI. Mechanism of facet load transmission as a hypothesis for low-back pain. *Spine*. 1984;9:557–565.
 28. Igarashi A, Kikuchi S, Konno S. Correlation between inflammatory cytokines released from the lumbar facet joint tissue and symptoms in degenerative lumbar spinal disorders. *J Orthop Sci*. 2007;12:154–160.
 29. Shealy CN. Facet denervation in the management of back and sciatic pain. *Clin Orthop Relat Res*. 1976;115:157–164.
 30. Shealy CN. Percutaneous radiofrequency denervation of spinal facets. *J Neurosurg*. 1975;43:448–451.
 31. Bogduk N, Long DM. The anatomy of the so-called “articular nerves” and their relationship to facet denervation in the treatment of low-back pain. *J Neurosurg*. 1979;51:172–177.
 32. Schwarzer AC, Aprill CN, Derby R, Fortin J, Kine G, Bogduk N. The false-positive rate of uncontrolled diagnostic blocks of the lumbar zygapophysial joints. *Pain*. 1994;58:195–200.
 33. Schwarzer AC, Wang SC, Bogduk N, McNaught PJ, Laurent R. Prevalence and clinical features of lumbar zyga-

popphysial joint pain: a study in an Australian population with chronic low back pain. *Ann Rheum Dis.* 1995;54:100–106.

34. Marks R. Distribution of pain provoked from lumbar facet joints and related structures during diagnostic spinal infiltration. *Pain.* 1989;39:37–40.

35. Fukui S, Ohseto K, Shiotani M, Ohno K, Karasawa H, Naganuma Y. Distribution of referred pain from the lumbar zygapophyseal joints and dorsal rami. *Clin J Pain.* 1997;13:303–307.

36. Fairbank JC, Park WM, McCall IW, O'Brien JP. Apophyseal injection of local anesthetic as a diagnostic aid in primary low-back pain syndromes. *Spine.* 1981;6:598–605.

37. Helbig T, Lee CK. The lumbar facet syndrome. *Spine.* 1988;13:61–64.

38. Schwarzer AC, Aprill CN, Derby R, Fortin J, Kine G, Bogduk N. The relative contributions of the disc and zygapophyseal joint in chronic low back pain. *Spine.* 1994;19:801–806.

39. Revel M, Poiraudou S, Auleley GR, et al. Capacity of the clinical picture to characterize low back pain relieved by facet joint anesthesia. Proposed criteria to identify patients with painful facet joints. *Spine.* 1998;23:1972–1976, discussion 7.

40. Cohen SP. Sacroiliac joint pain: a comprehensive review of anatomy, diagnosis, and treatment. *Anesth Analg.* 2005;101:1440–1453.

41. Laslett M, McDonald B, Aprill CN, Tropp H, Oberg B. Clinical predictors of screening lumbar zygapophyseal joint blocks: development of clinical prediction rules. *Spine J.* 2006;6:370–379.

42. Ianuzzi A, Little JS, Chiu JB, Baitner A, Kawchuk G, Khalsa PS. Human lumbar facet joint capsule strains: I. During physiological motions. *Spine J.* 2004;4:141–152.

43. Jackson RP, Jacobs RR, Montesano PX. 1988 Volvo award in clinical sciences. Facet joint injection in low-back pain. A prospective statistical study. *Spine.* 1988;13:966–971.

44. Schwarzer AC, Aprill CN, Derby R, Fortin J, Kine G, Bogduk N. Clinical features of patients with pain stemming from the lumbar zygapophysial joints. Is the lumbar facet syndrome a clinical entity? *Spine.* 1994;19:1132–1137.

45. Laslett M, Oberg B, Aprill CN, McDonald B. Zygapophysial joint blocks in chronic low back pain: a test of Revel's model as a screening test. *BMC Musculoskelet Disord.* 2004;5:43.

46. Cohen SP, Hurley RW, Christo PJ, Winkley J, Mohiuddin MM, Stojanovic MP. Clinical predictors of success and failure for lumbar facet radiofrequency denervation. *Clin J Pain.* 2007;23:45–52.

47. Wilde VE, Ford JJ, McMeeken JM. Indicators of lumbar zygapophyseal joint pain: survey of an expert panel with the Delphi technique. *Phys Ther.* 2007;87:1348–1361.

48. Cohen SP, Argoff CE, Carragee EJ. Management of low back pain. *BMJ.* 2008;337:a2718.

49. Weishaupt D, Zanetti M, Boos N, Hodler J. MR imaging and CT in osteoarthritis of the lumbar facet joints. *Skeletal Radiol.* 1999;28:215–219.

50. Carrera GF, Williams AL. Current concepts in evaluation of the lumbar facet joints. *Crit Rev Diagn Imaging.* 1984;21:85–104.

51. Dolan AL, Ryan PJ, Arden NK, et al. The value of SPECT scans in identifying back pain likely to benefit from facet joint injection. *Br J Rheumatol.* 1996;35:1269–1273.

52. Schwarzer AC, Wang SC, O'Driscoll D, Harrington T, Bogduk N, Laurent R. The ability of computed tomography to identify a painful zygapophysial joint in patients with chronic low back pain. *Spine.* 1995;20:907–912.

53. Airaksinen O, Brox JL, Cedraschi C, et al. Chapter 4. European guidelines for the management of chronic nonspecific low back pain. *Eur Spine J.* 2006;15(suppl 2):S192–S300.

54. Greher M, Kirchmair L, Enna B, et al. Ultrasound-guided lumbar facet nerve block: accuracy of a new technique confirmed by computed tomography. *Anesthesiology.* 2004;101:1195–1200.

55. Shim JK, Moon JC, Yoon KB, Kim WO, Yoon DM. Ultrasound-guided lumbar medial-branch block: a clinical study with fluoroscopy control. *Reg Anesth Pain Med.* 2006;31:451–454.

56. Kaplan M, Dreyfuss P, Halbrook B, Bogduk N. The ability of lumbar medial branch blocks to anesthetize the zygapophysial joint. A physiologic challenge. *Spine (Phila Pa 1976).* 1998;23:1847–1852.

57. Dreyfuss P, Schwarzer AC, Lau P, Bogduk N. Specificity of lumbar medial branch and L5 dorsal ramus blocks. A computed tomography study. *Spine.* 1997;22:895–902.

58. Ackerman WE, Munir MA, Zhang JM, Ghaleb A. Are diagnostic lumbar facet injections influenced by pain of muscular origin? *Pain Pract.* 2004;4:286–291.

59. Cohen SP, Larkin TM, Chang AS, Stojanovic MP. The causes of false-positive medial branch (facet joint) blocks in soldiers and retirees. *Mil Med.* 2004;169:781–786.

60. Kellegren J. On the distribution of pain arising from deep somatic structures with charts of segmental pain areas. *Clin Sci.* 1939;4:35–46.

61. Lord SM, Barnsley L, Bogduk N. The utility of comparative local anesthetic blocks versus placebo-controlled blocks for the diagnosis of cervical zygapophysial joint pain. *Clin J Pain.* 1995;11:208–213.

62. O'Neill C, Owens DK. Lumbar facet joint pain: time to hit the reset button. *Spine J.* 2009;9:619–622.

63. Bogduk N, Holmes S. Controlled zygapophysial joint blocks: the travesty of cost-effectiveness. *Pain Med.* 2000;1:24–34.

64. Schnitzer TJ, Ferraro A, Hunsche E, Kong SX. A comprehensive review of clinical trials on the efficacy and safety of drugs for the treatment of low back pain. *J Pain Symptom Manage.* 2004;28:72–95.

65. Andersson GB, Lucente T, Davis AM, Kappler RE, Lipton JA, Leurgans S. A comparison of osteopathic spinal manipulation with standard care for patients with low back pain. *N Engl J Med*. 1999;341:1426–1431.
66. Giles LG, Muller R. Chronic spinal pain: a randomized clinical trial comparing medication, acupuncture, and spinal manipulation. *Spine*. 2003;28:1490–1502, discussion 502–503.
67. Licciardone JC, Stoll ST, Fulda KG, et al. Osteopathic manipulative treatment for chronic low back pain: a randomized controlled trial. *Spine*. 2003;28:1355–1362.
68. Silvers HR. Lumbar percutaneous facet rhizotomy. *Spine (Phila Pa 1976)*. 1990;15:36–40.
69. Schofferman J, Kine G. Effectiveness of repeated radiofrequency neurotomy for lumbar facet pain. *Spine*. 2004;29:2471–2473.
70. Lilius G, Laasonen EM, Myllynen P, Harilainen A, Salo L. [Lumbar facet joint syndrome. Significance of non-organic signs. A randomized placebo-controlled clinical study]. *Rev Chir Orthop Reparatrice Appar Mot*. 1989;75:493–500.
71. Carette S, Marcoux S, Truchon R, et al. A controlled trial of corticosteroid injections into facet joints for chronic low back pain. *N Engl J Med*. 1991;325:1002–1007.
72. Egsomose C, Lund B, Bach Andersen R. Hip joint distension in osteoarthritis. A triple-blind controlled study comparing the effect of intra-articular indoprofen with placebo. *Scand J Rheumatol*. 1984;13:238–242.
73. Pneumaticos SG, Chatziioannou SN, Hipp JA, Moore WH, Esses SI. Low back pain: prediction of short-term outcome of facet joint injection with bone scintigraphy. *Radiology*. 2006;238:693–698.
74. Holder LE, Machin JL, Asdourian PL, Links JM, Sexton CC. Planar and high-resolution SPECT bone imaging in the diagnosis of facet syndrome. *J Nucl Med*. 1995;36:37–44.
75. Gallagher J, Vadi PLP, Wesley JR. Radiofrequency facet joint denervation in the treatment of low back pain—a prospective controlled double-blind study to assess its efficacy. *Pain Clinic*. 1994;7:193–198.
76. van Kleef M, Barendse GA, Kessels F, Voets HM, Weber WE, de Lange S. Randomized trial of radiofrequency lumbar facet denervation for chronic low back pain. *Spine*. 1999;24:1937–1942.
77. Leclaire R, Fortin L, Lambert R, Bergeron YM, Rossignol M. Radiofrequency facet joint denervation in the treatment of low back pain: a placebo-controlled clinical trial to assess efficacy. *Spine*. 2001;26:1411–1416, discussion 7.
78. van Wijk RM, Geurts JW, Wynne HJ, et al. Radiofrequency denervation of lumbar facet joints in the treatment of chronic low back pain: a randomized, double-blind, sham lesion-controlled trial. *Clin J Pain*. 2005;21:335–344.
79. Tekin I, Mirzai H, Ok G, Erbuynun K, Vatansever D. A comparison of conventional and pulsed radiofrequency denervation in the treatment of chronic facet joint pain. *Clin J Pain*. 2007;23:524–529.
80. Kroll HR, Kim D, Danic MJ, Sankey SS, Gariwala M, Brown M. A randomized, double-blind, prospective study comparing the efficacy of continuous versus pulsed radiofrequency in the treatment of lumbar facet syndrome. *J Clin Anesth*. 2008;20:534–537.
81. Chou R, Atlas SJ, Stanos SP, Rosenquist RW. Non-surgical interventional therapies for low back pain: a review of the evidence for an American Pain Society clinical practice guideline. *Spine (Phila Pa 1976)*. 2009;34:1078–1093.
82. Van Zundert J, Vanelderden P, Kessels A. Re: Chou R, Atlas SJ, Stanos SP, et al. Nonsurgical interventional therapies for low back pain: a review of the evidence for an American Pain Society clinical practice guideline. *Spine (Phila Pa 1976)* 2009;34:1078–1093. *Spine (Phila Pa 1976)* 2010;35:841; author reply 841–842.
83. Kornick C, Kramarich SS, Lamer TJ, Todd Sitzman B. Complications of lumbar facet radiofrequency denervation. *Spine*. 2004;29:1352–1354.
84. Cheng J, Abdi S. Complications of joint, tendon, and muscle injections. *Tech Reg Anesth Pain Manag*. 2007;11:141–147.
85. Ogsbury JS 3rd, Simon RH, Lehman RA. Facet “denervation” in the treatment of low back syndrome. *Pain*. 1977;3:257–263.
86. Lau P, Mercer S, Govind J, Bogduk N. The surgical anatomy of lumbar medial branch neurotomy (facet denervation). *Pain Med*. 2004;5:289–298.
87. Bogduk N, Macintosh J, Marsland A. Technical limitations to the efficacy of radiofrequency neurotomy for spinal pain. *Neurosurgery*. 1987;20:529–535.